Dermatopathology Slide Review Part 103

Paul K. Shitabata, M.D.
Dermatopathology Institute
Torrance, CA

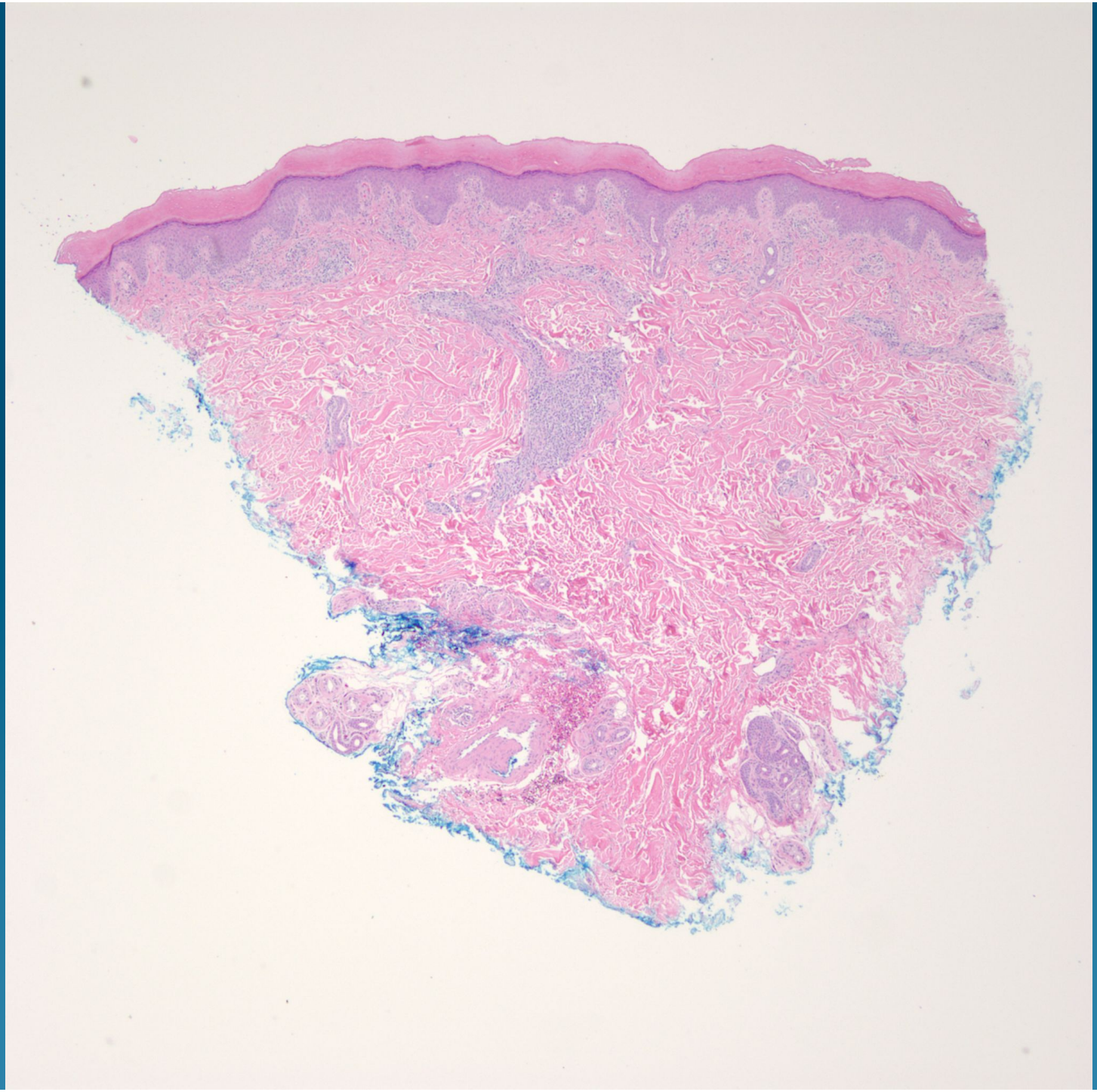

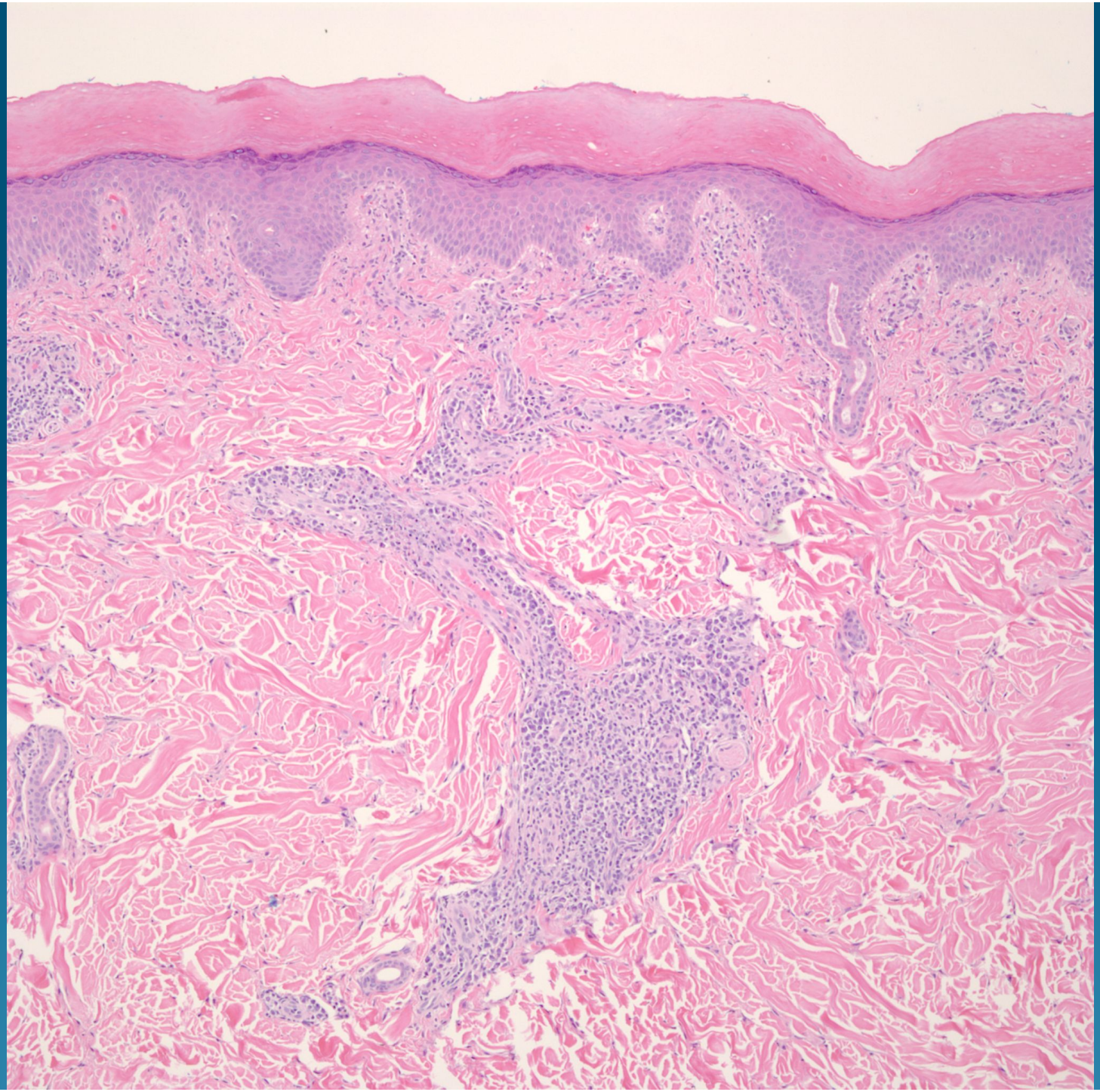

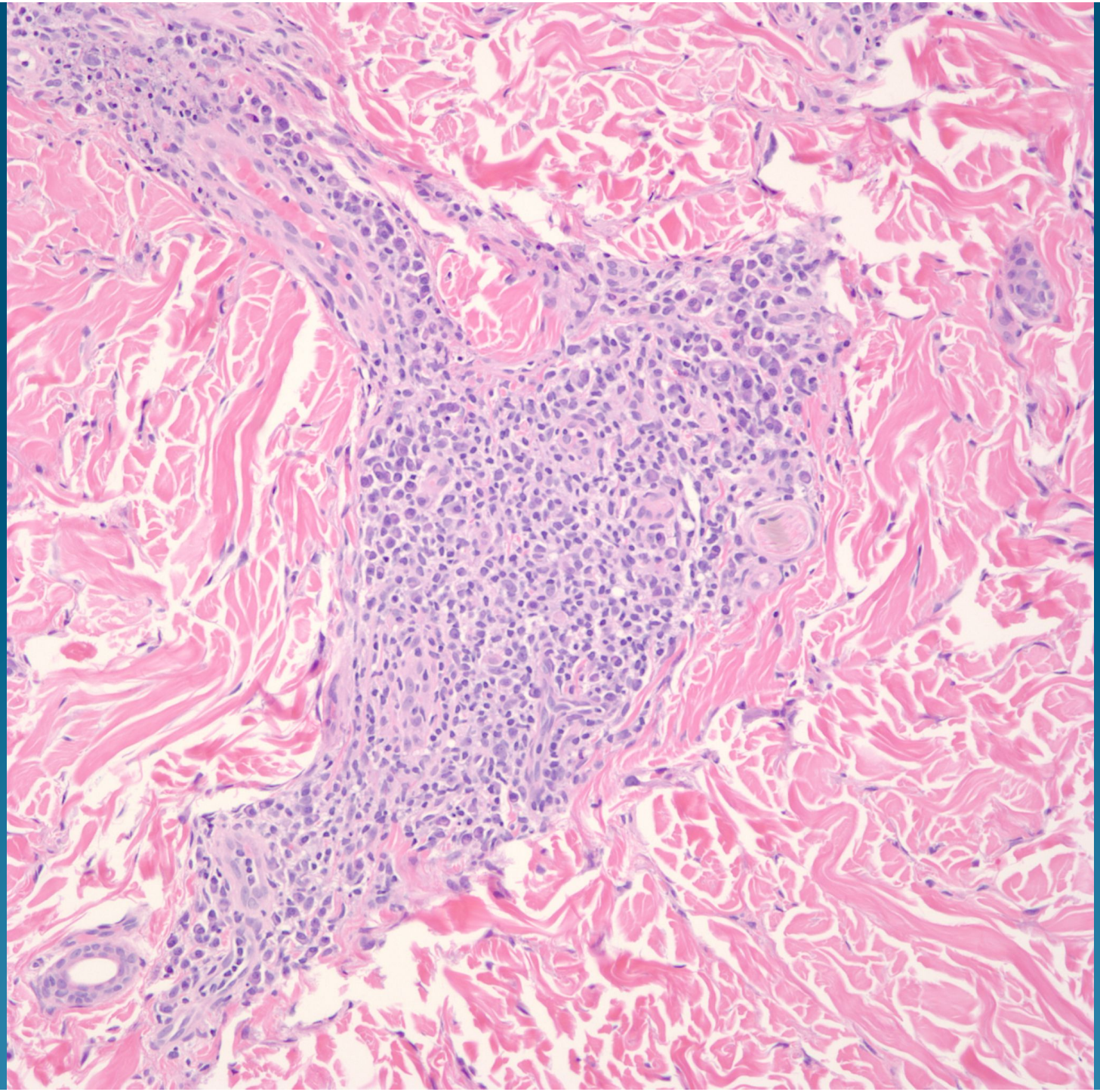

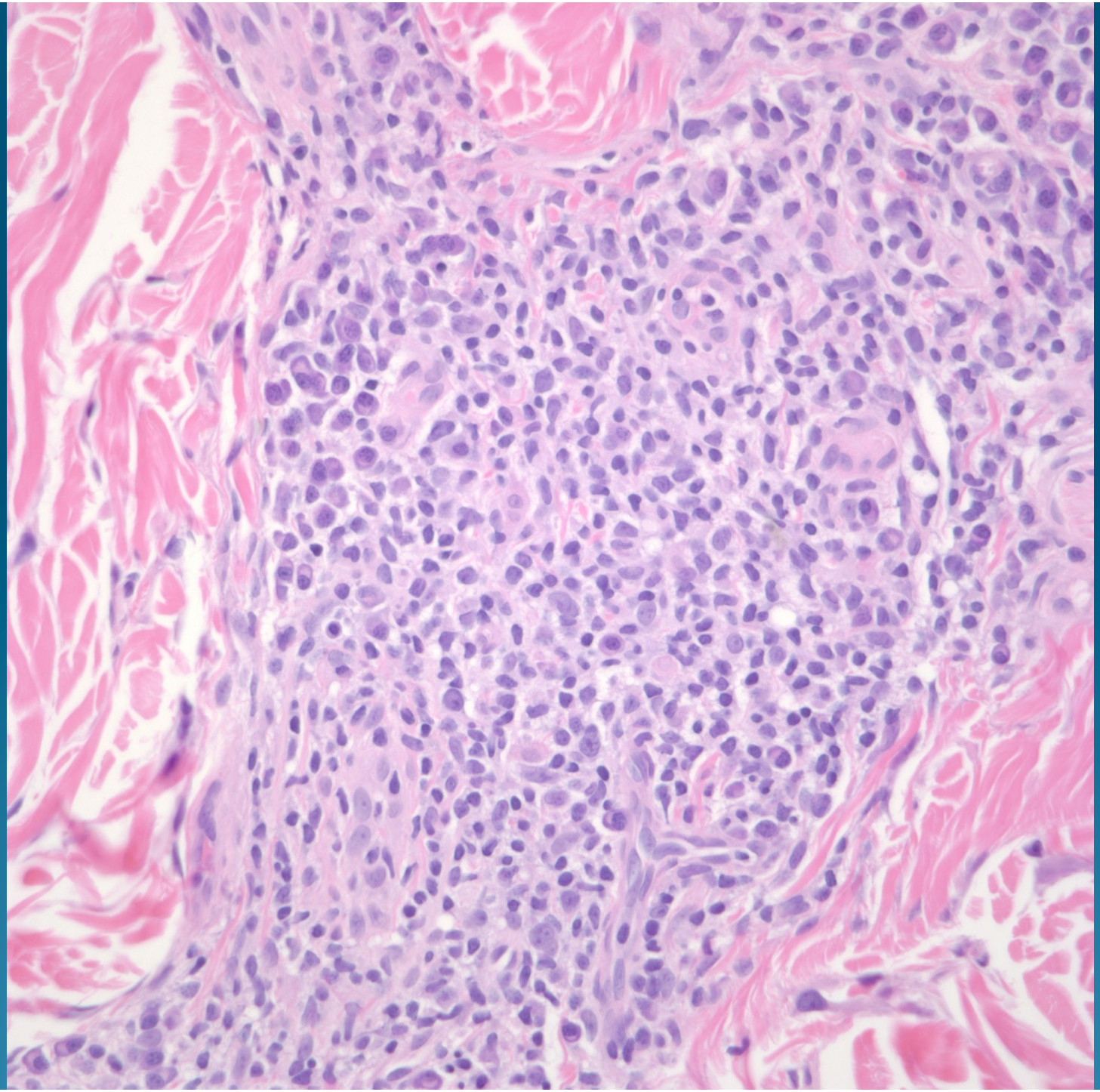

Secondary Syphilis

Warthin-Starry stain negative
Positive VDRL

Pearls

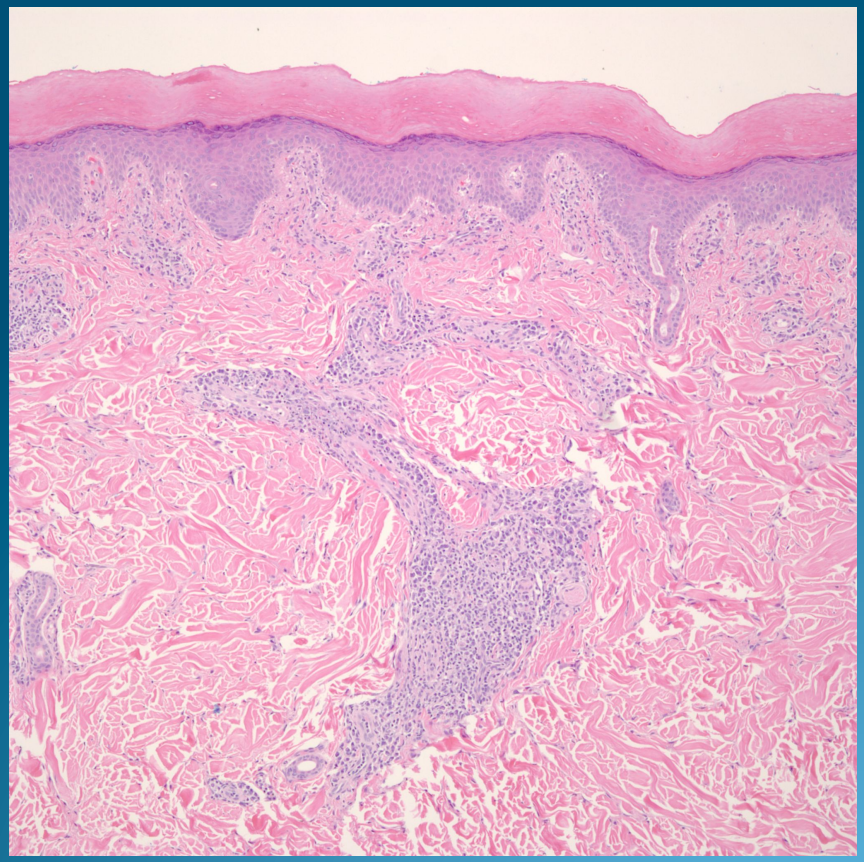

- Variable spongiotic and epidermal changes associated with a superficial perivascular dermatitis with numerous plasma cells
- Warthin-Starry stain may show spirochete organisms at the dermal-epidermal junction and around endothelial cells
- Confirm with serological studies and clinical correlation

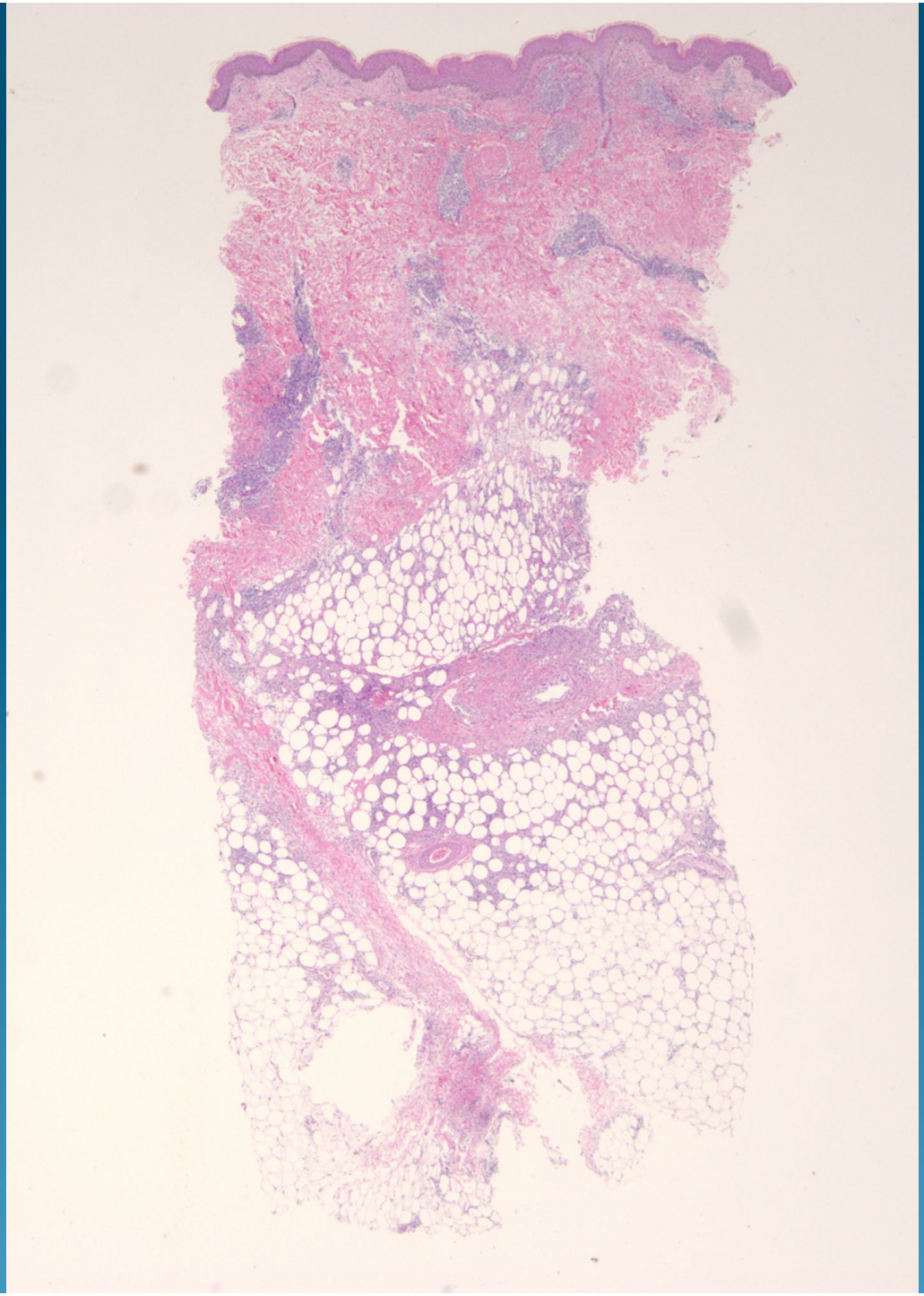

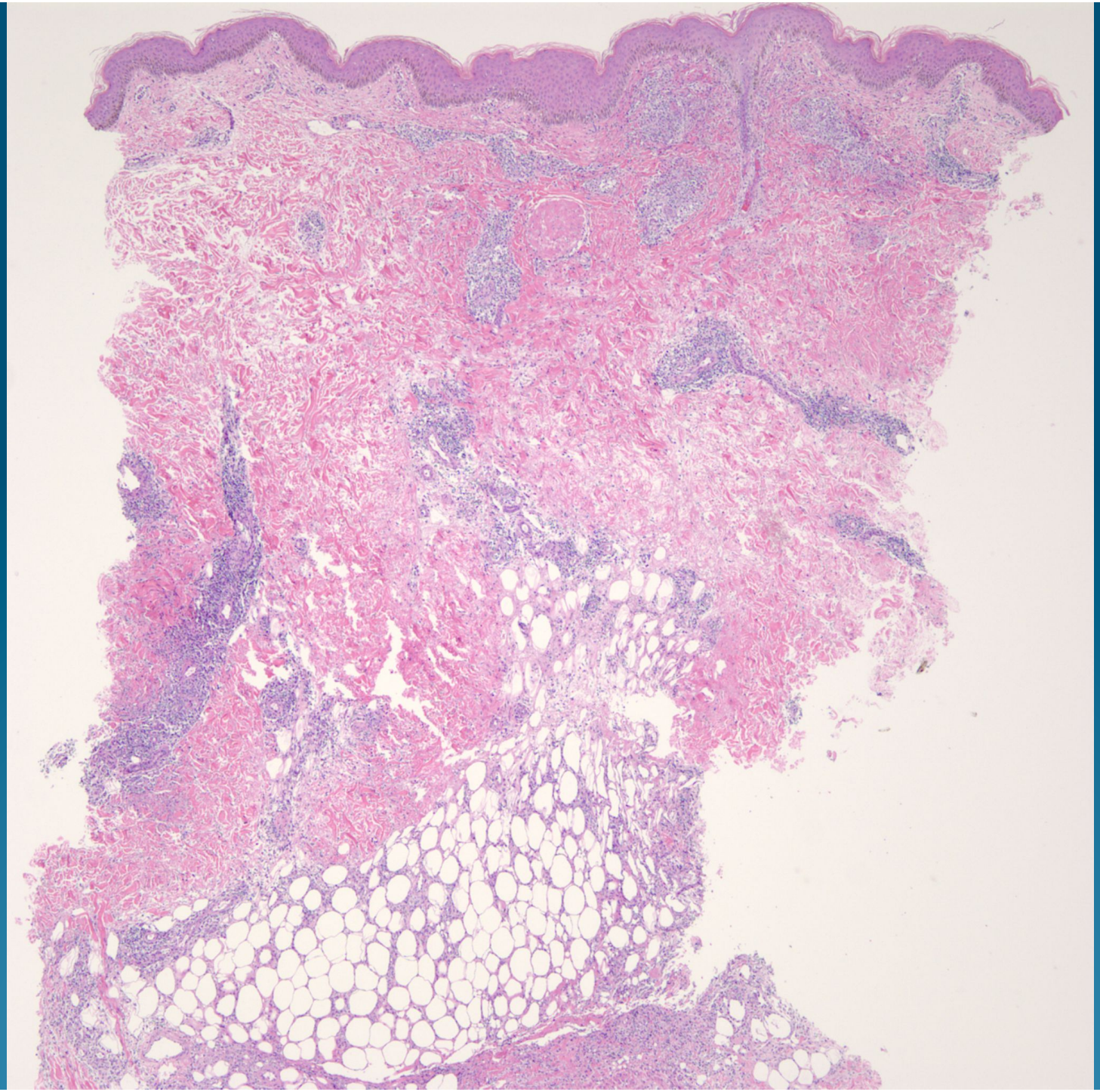

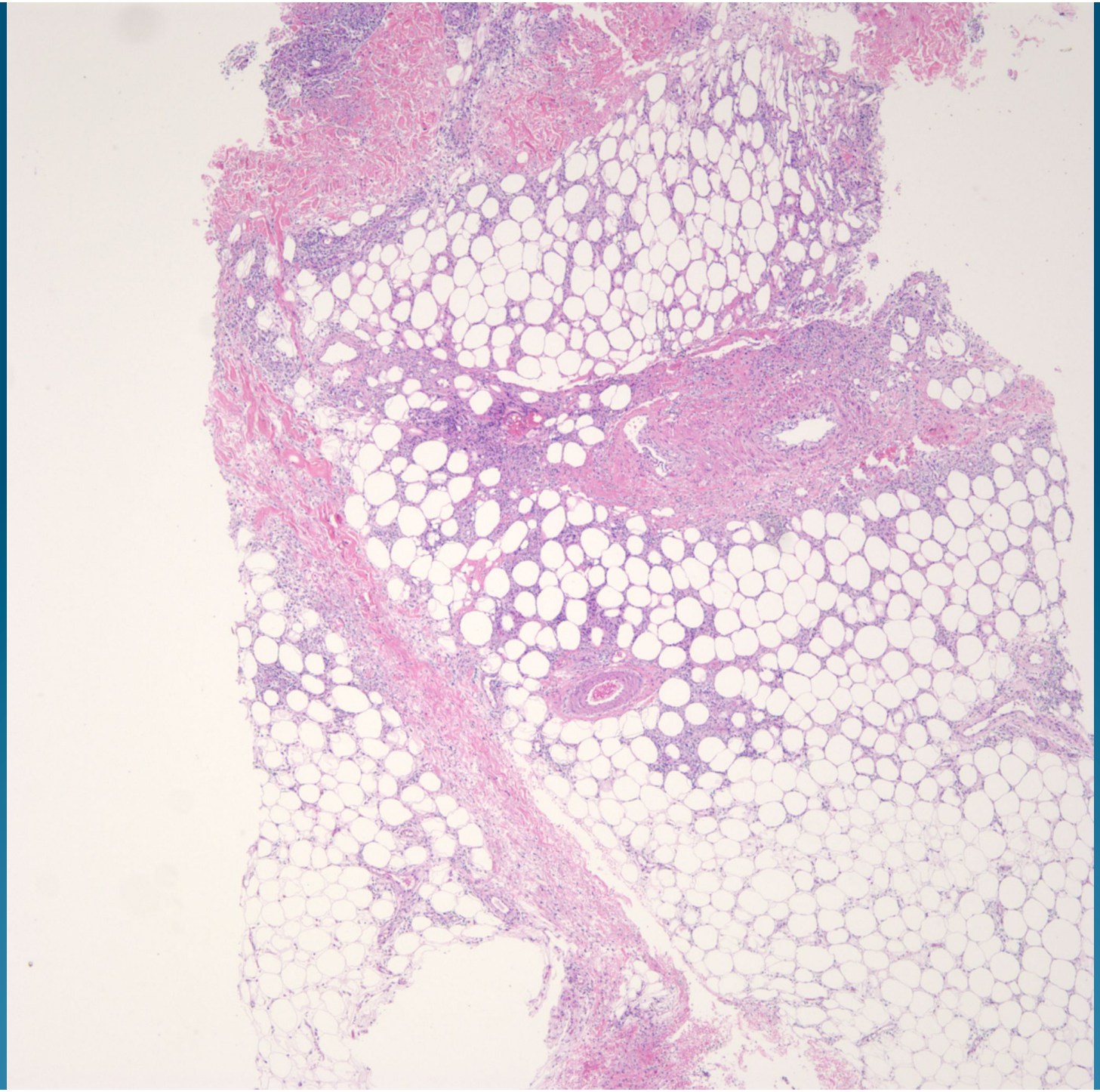

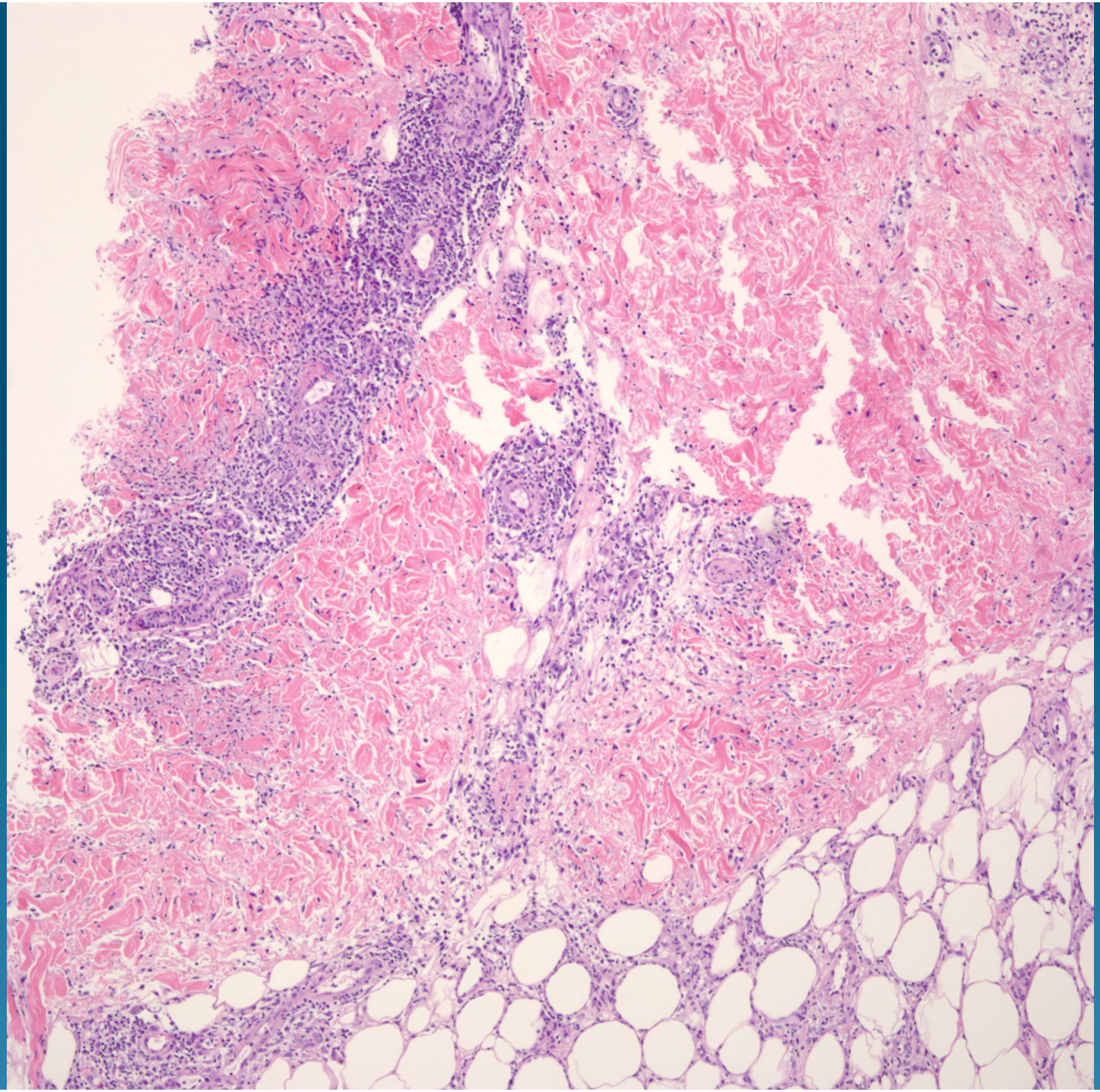

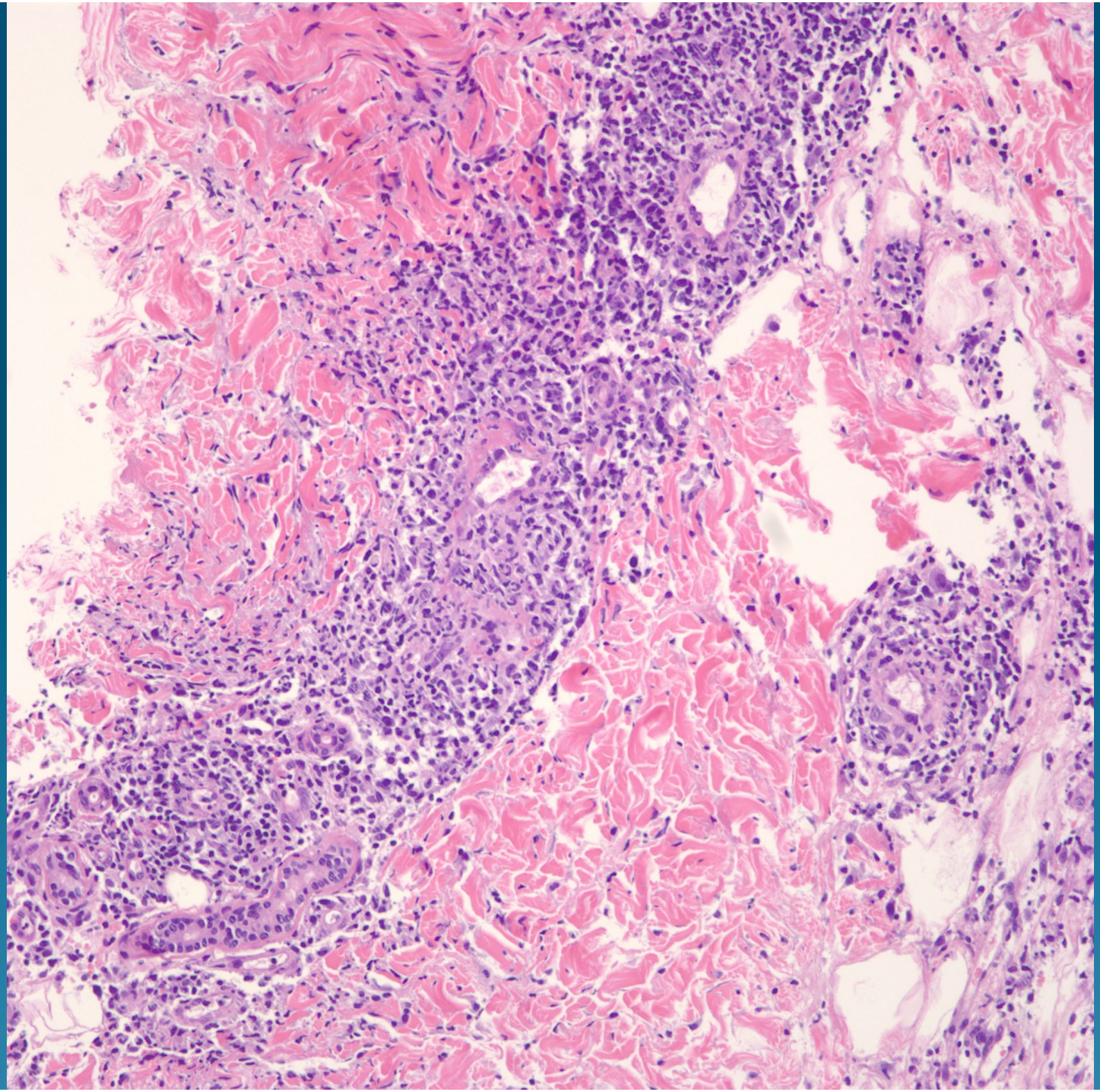

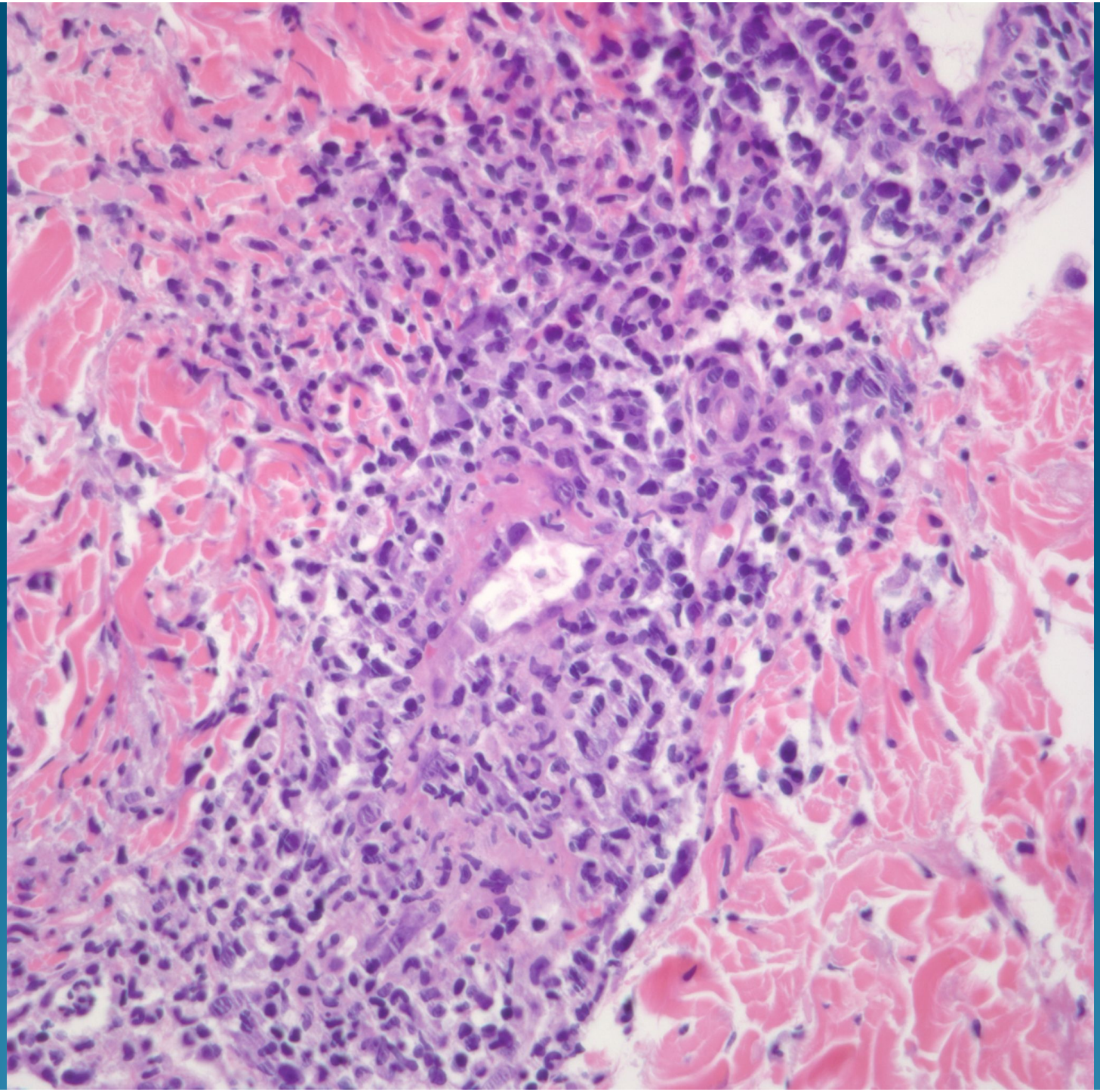

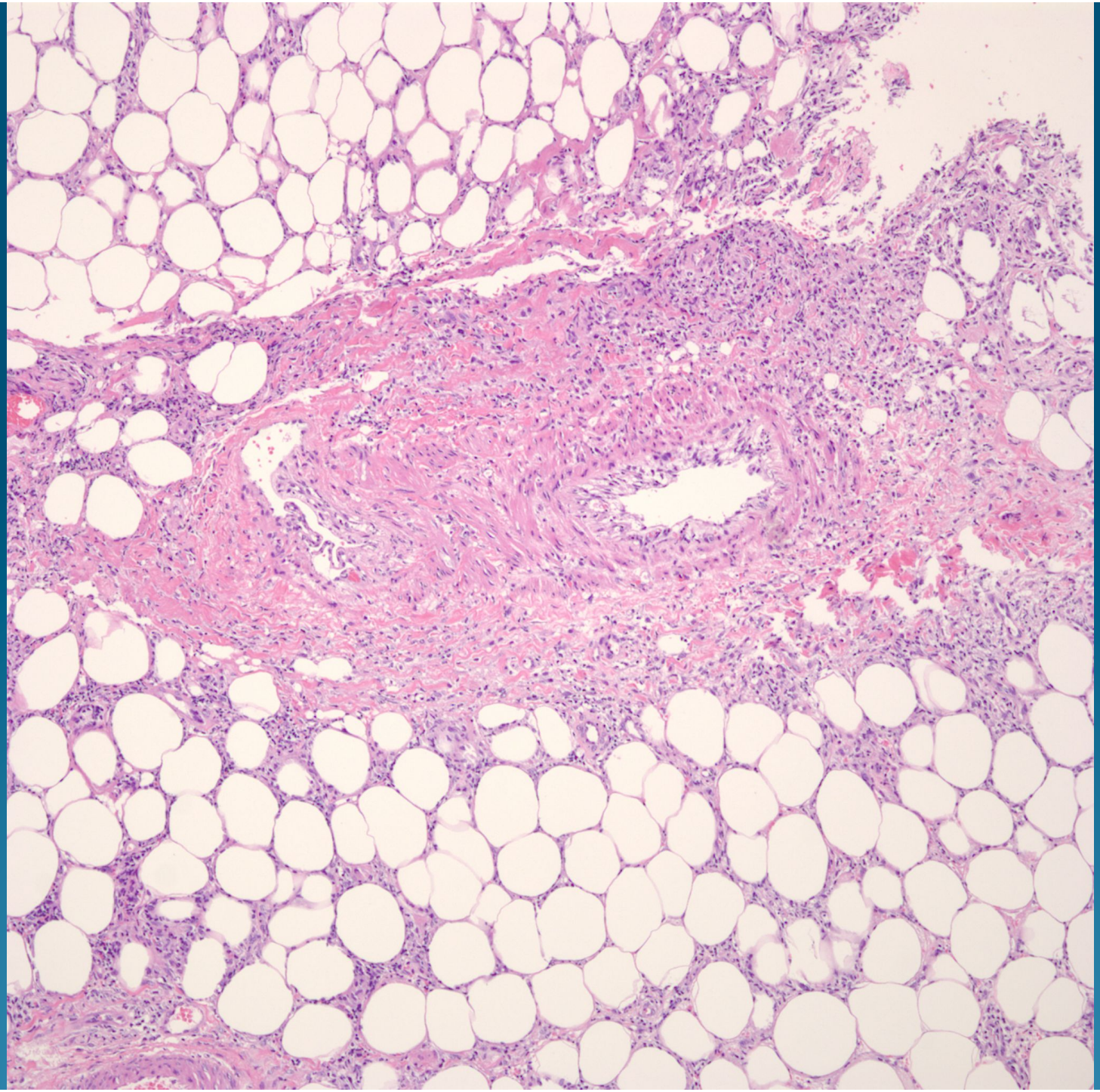

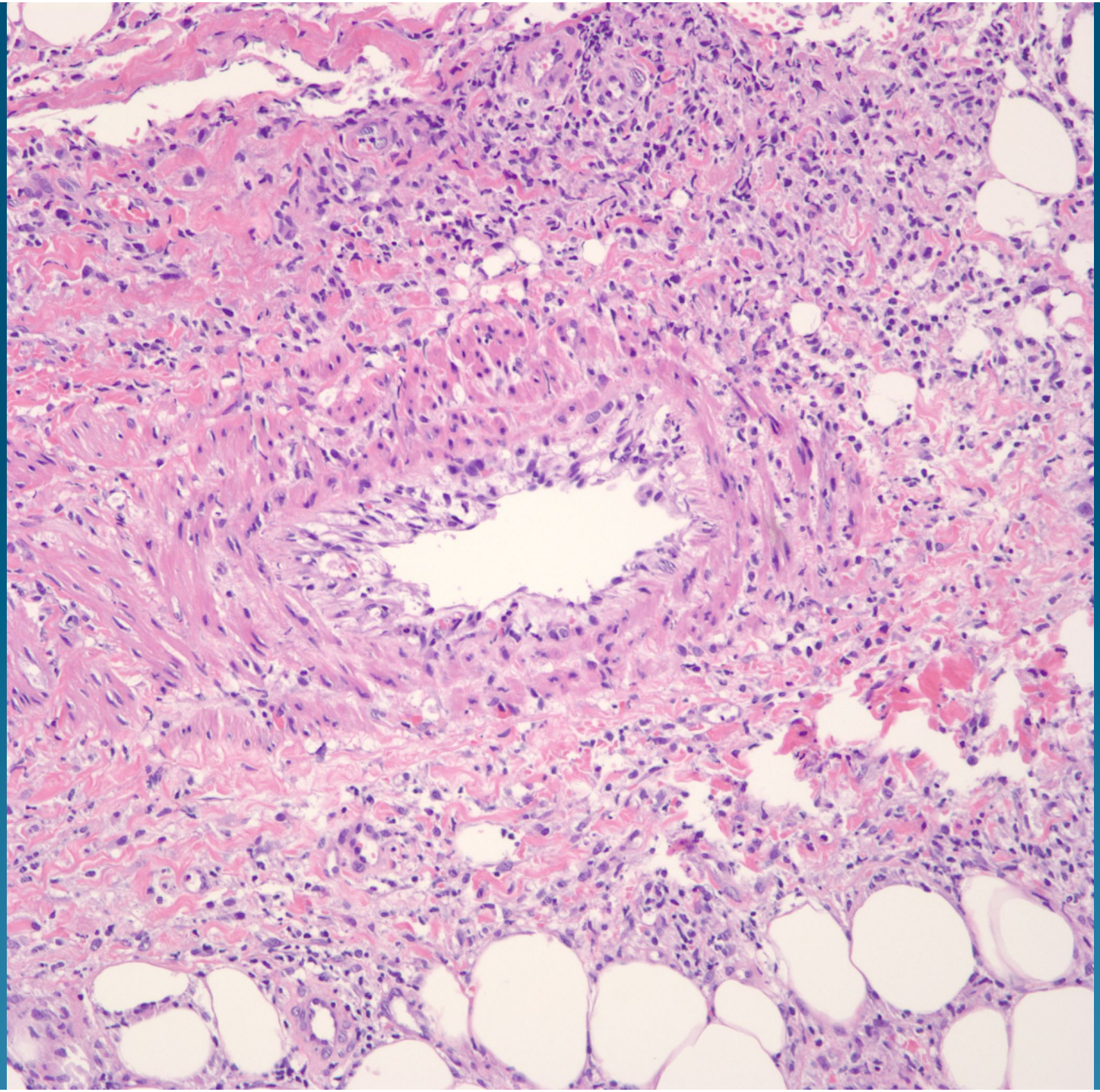

Erythema induratum
(Nodular vasculitis)

Patient with active M. tuberculosis
AFB, FITE, PAS stains negative for micro-organisms

Pearls

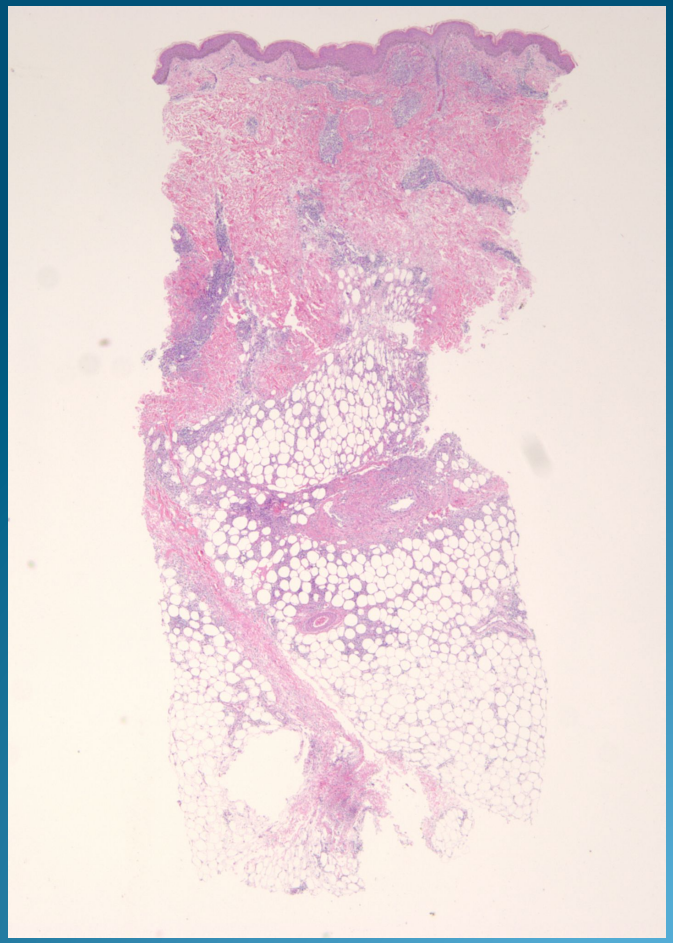

- Variable histopathology depending upon stage of disease but varies from septal, mixed, to lobular panniculitis
- Scattered granulomatous infiltrate with variable caseous necrosis
- Vasculitis, both leukocytoclastic and medium-sized vessels.
- DDX: Erythema nodosum which usually lacks vasculitis

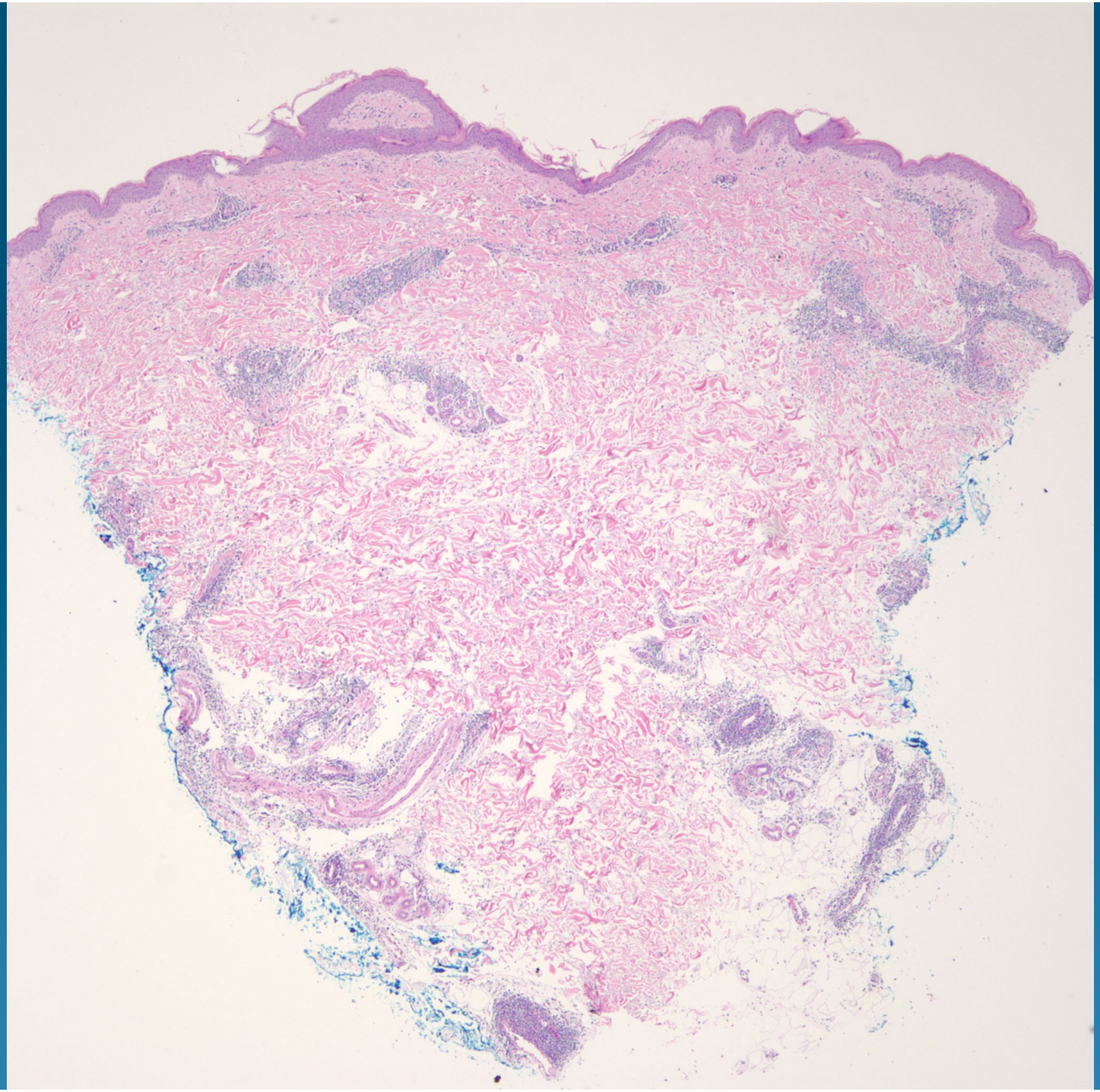

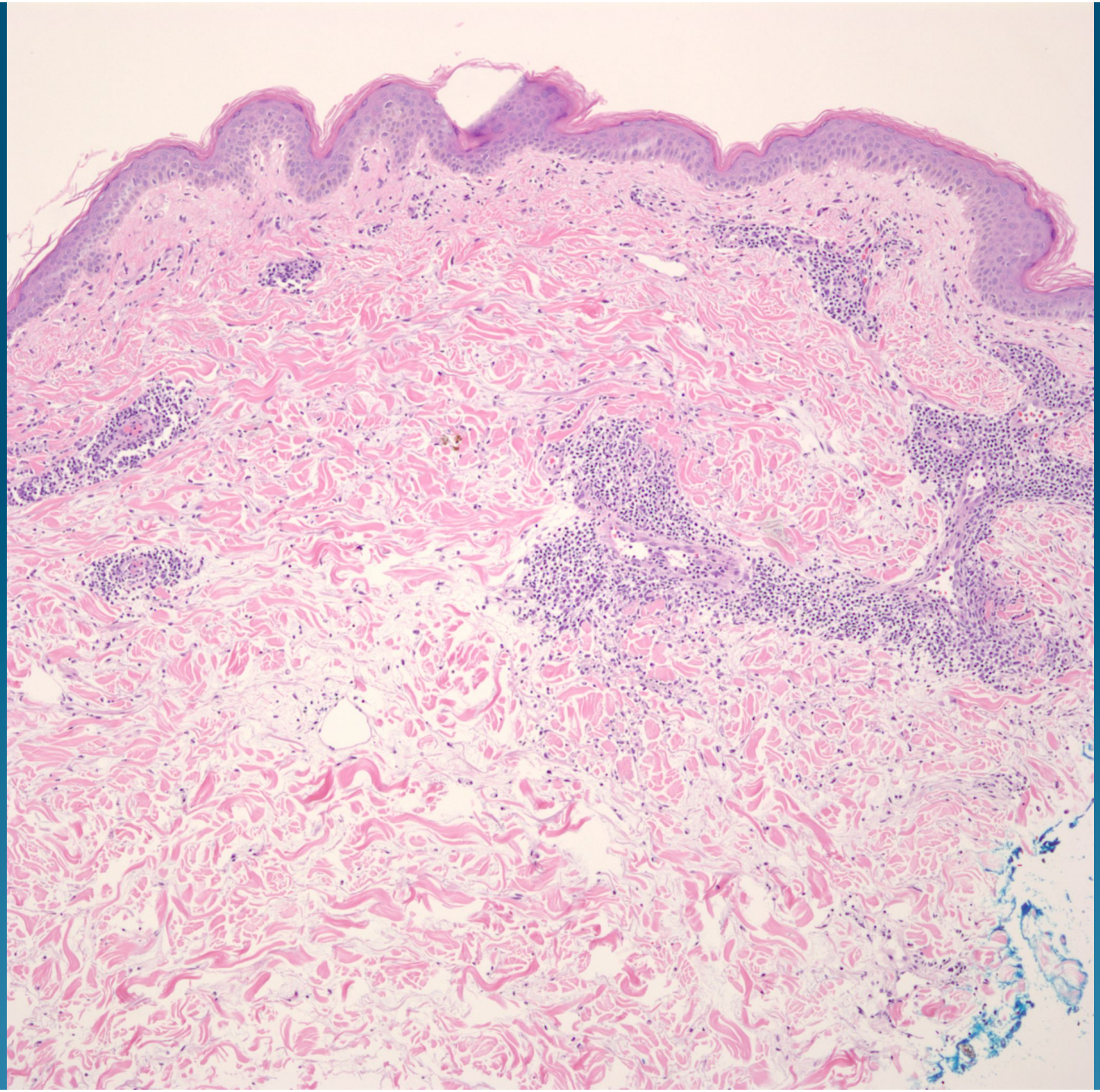

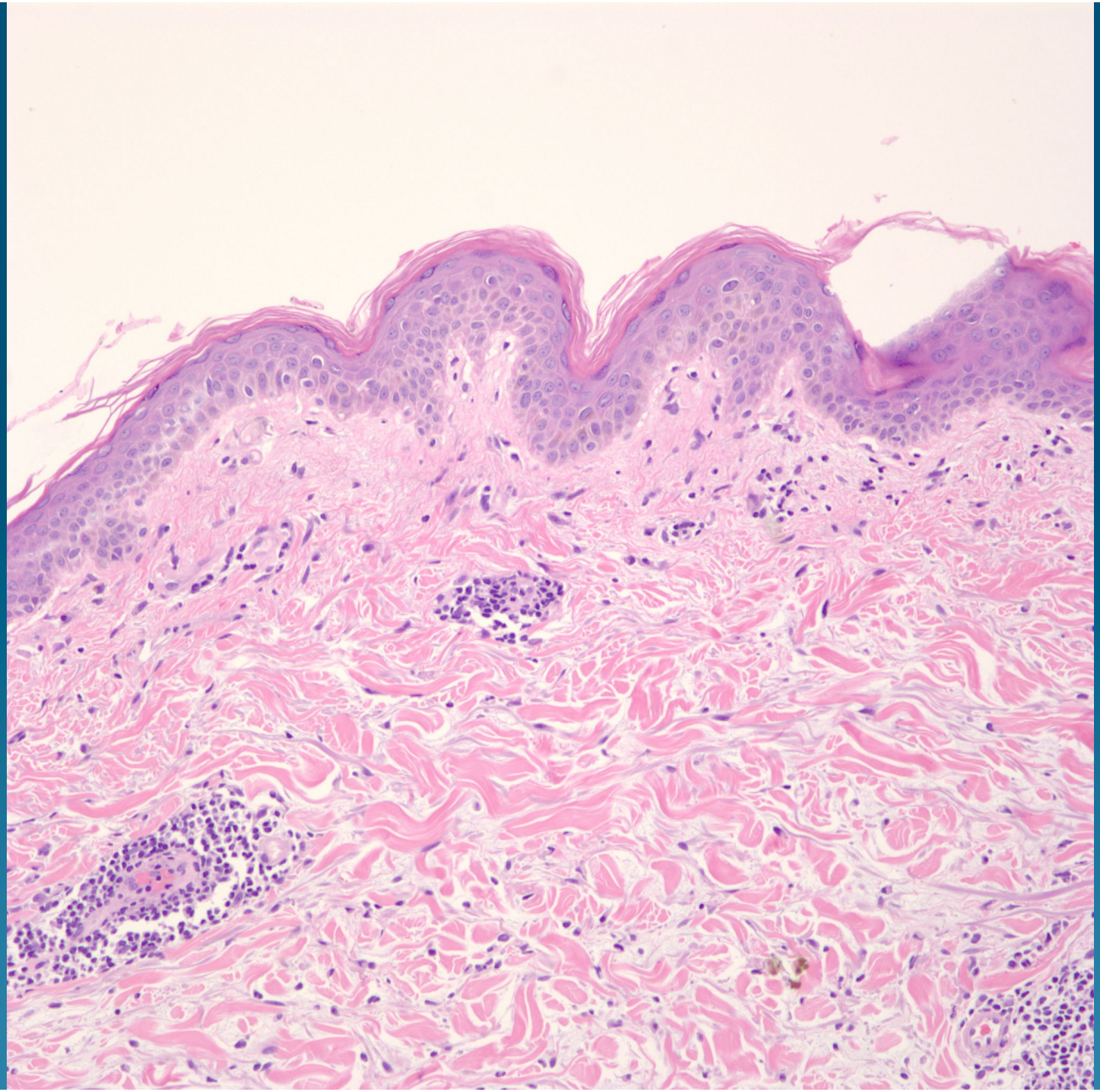

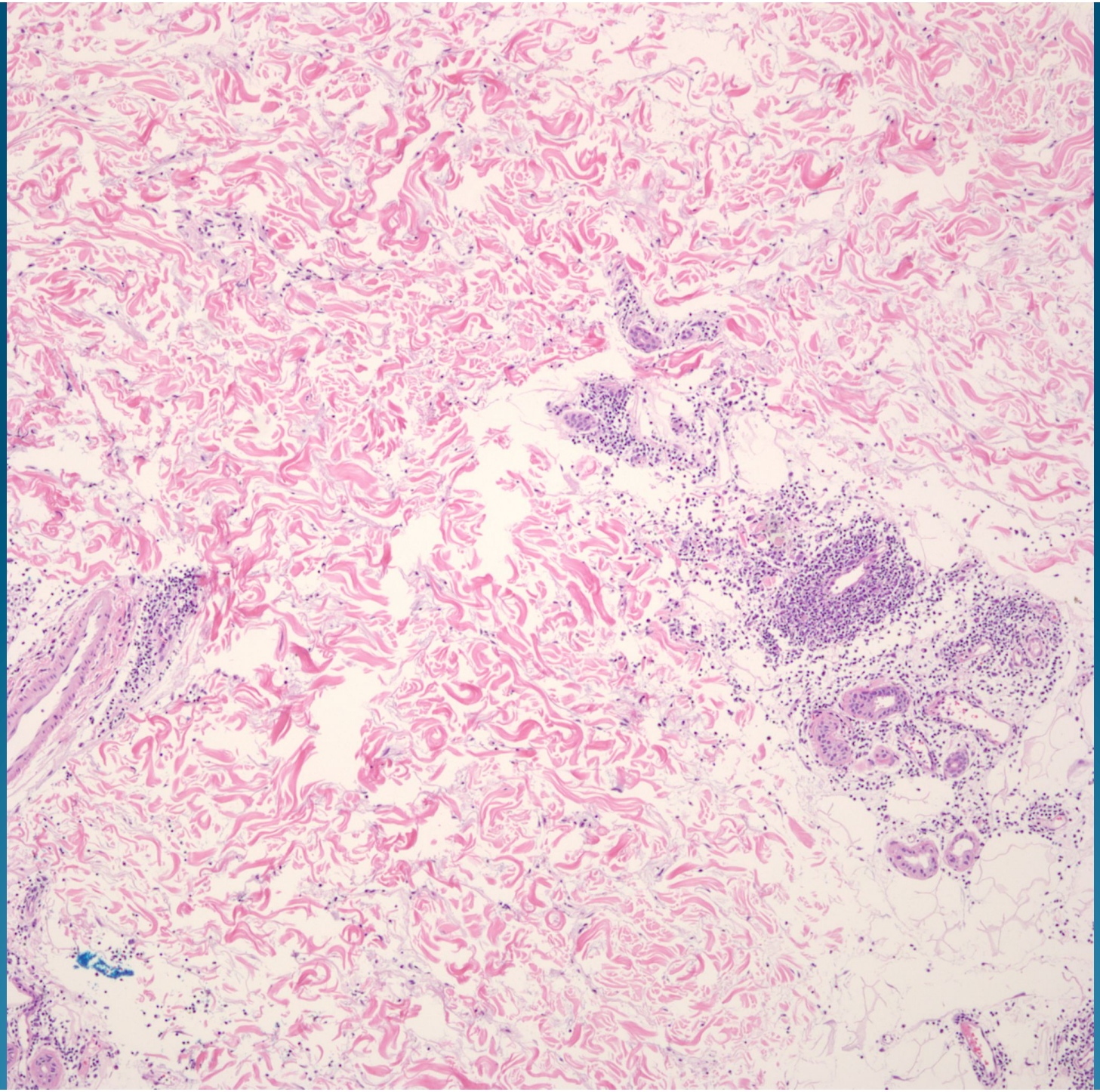

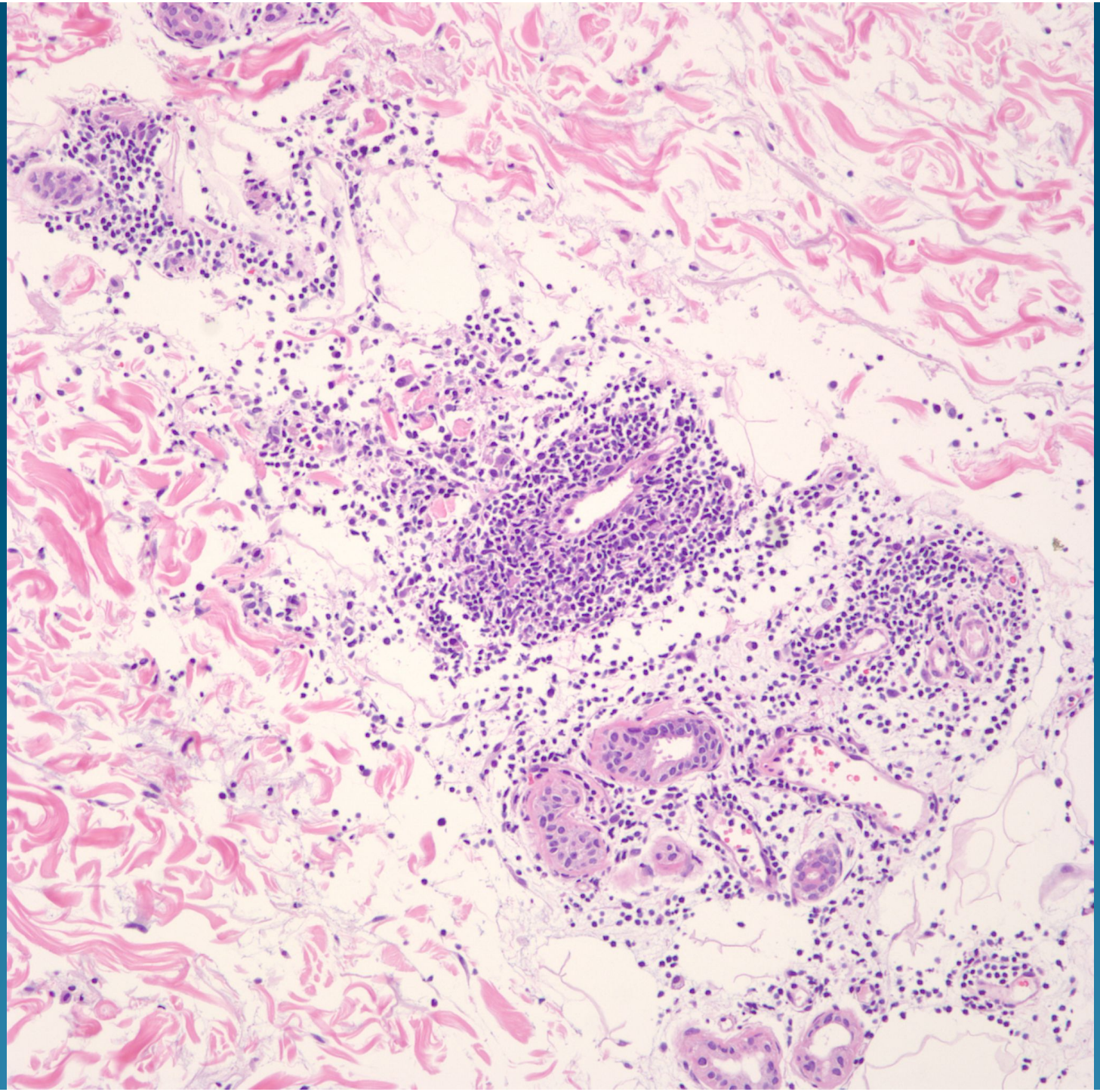

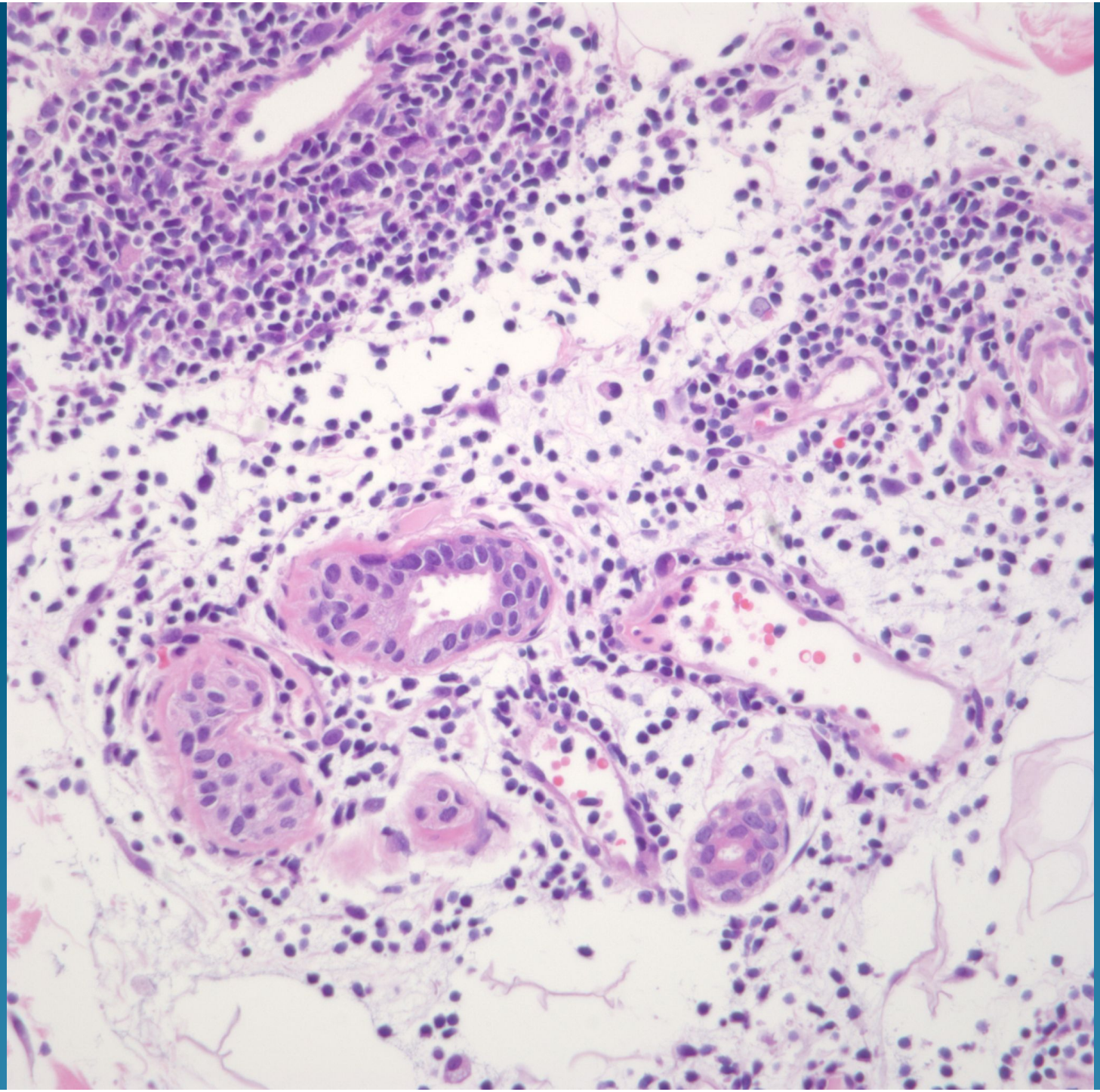

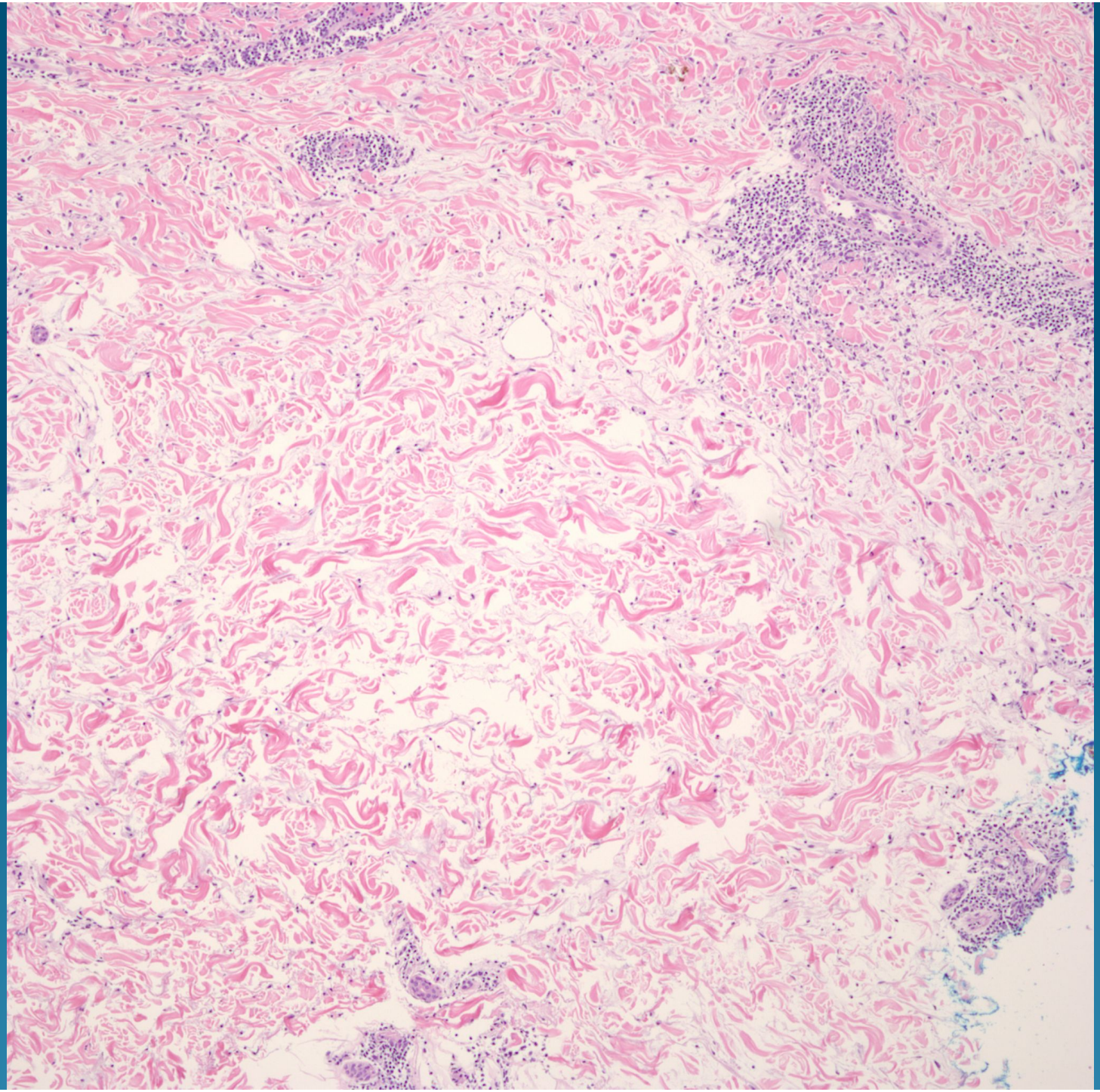

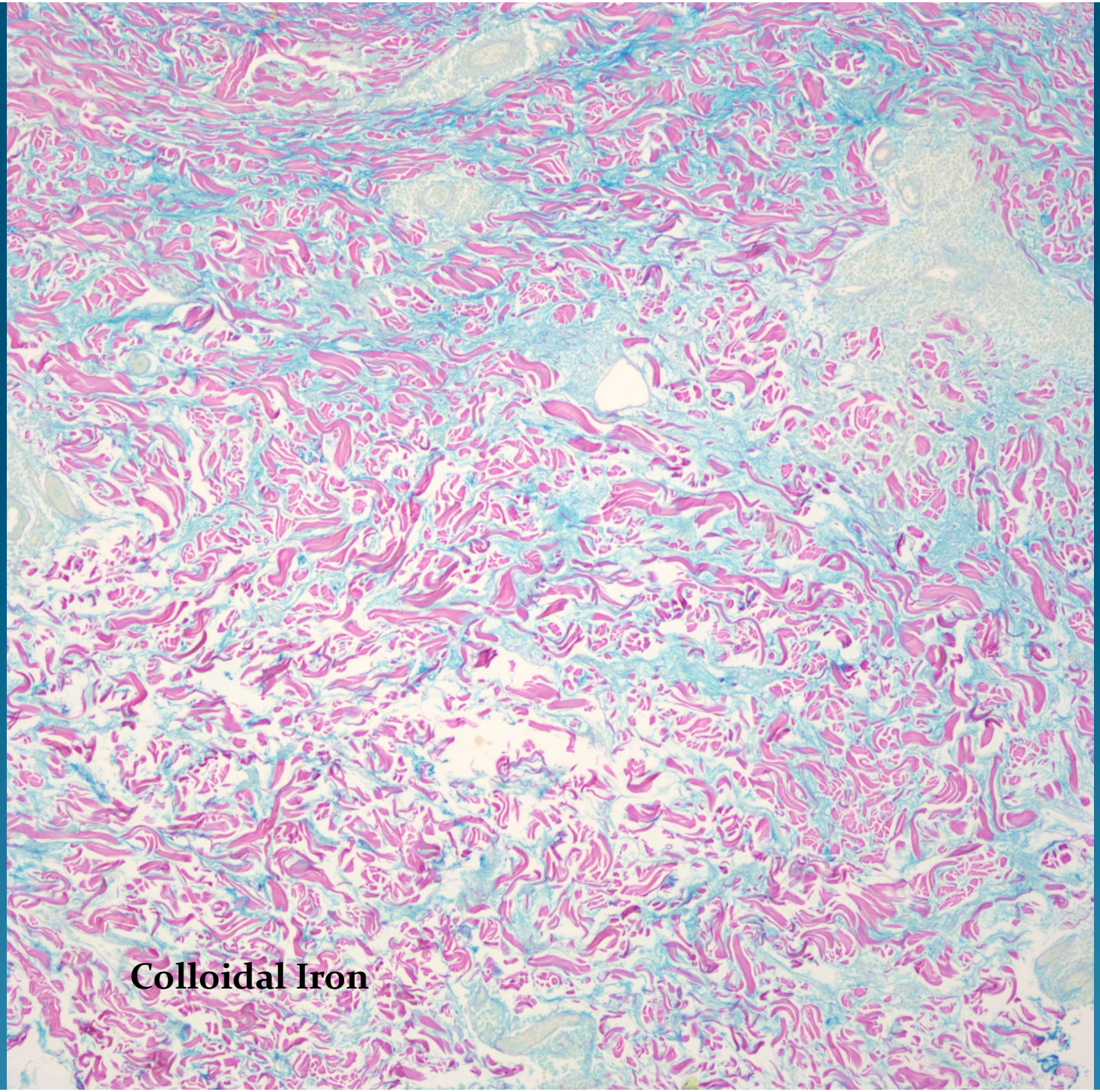
Colloidal Iron

Discoid Lupus Erythematosus

Pearls

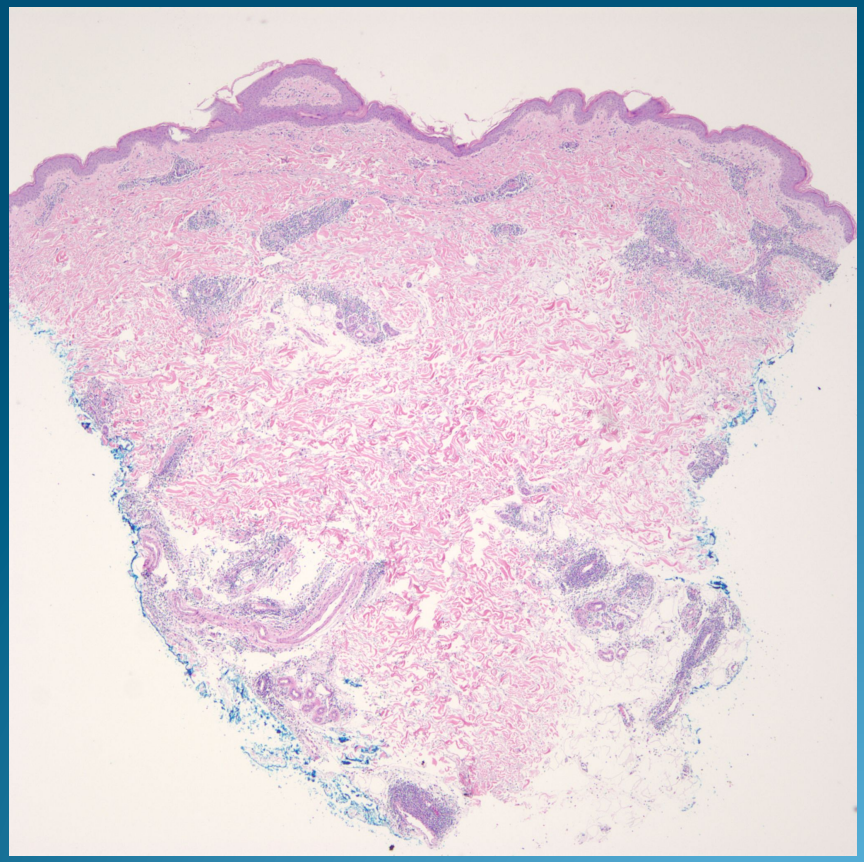

- Superficial and deep perivascular and periadnexal lymphocytic infiltrate
- Variable interface dermatitis
- Dermal mucinosis

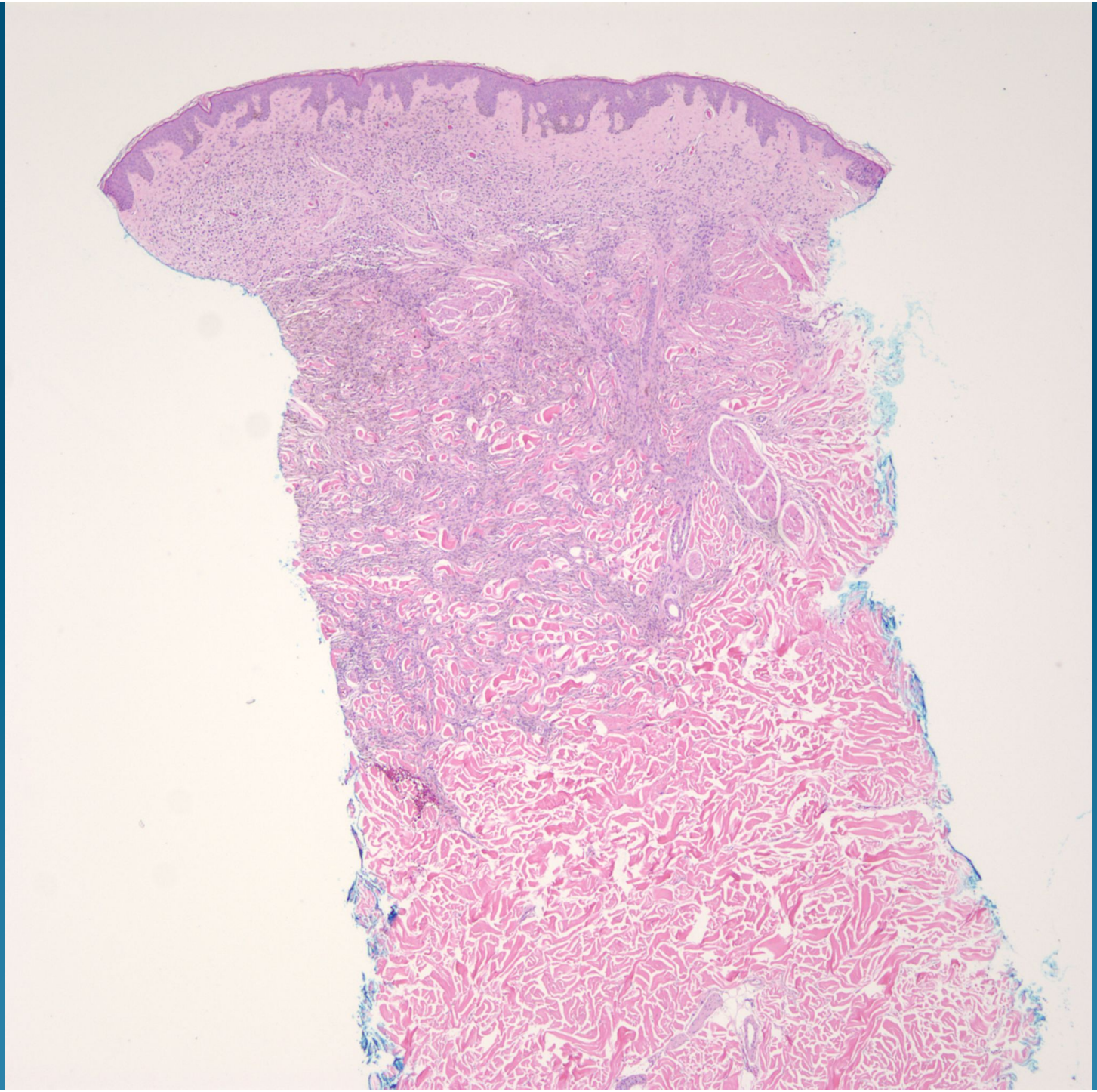

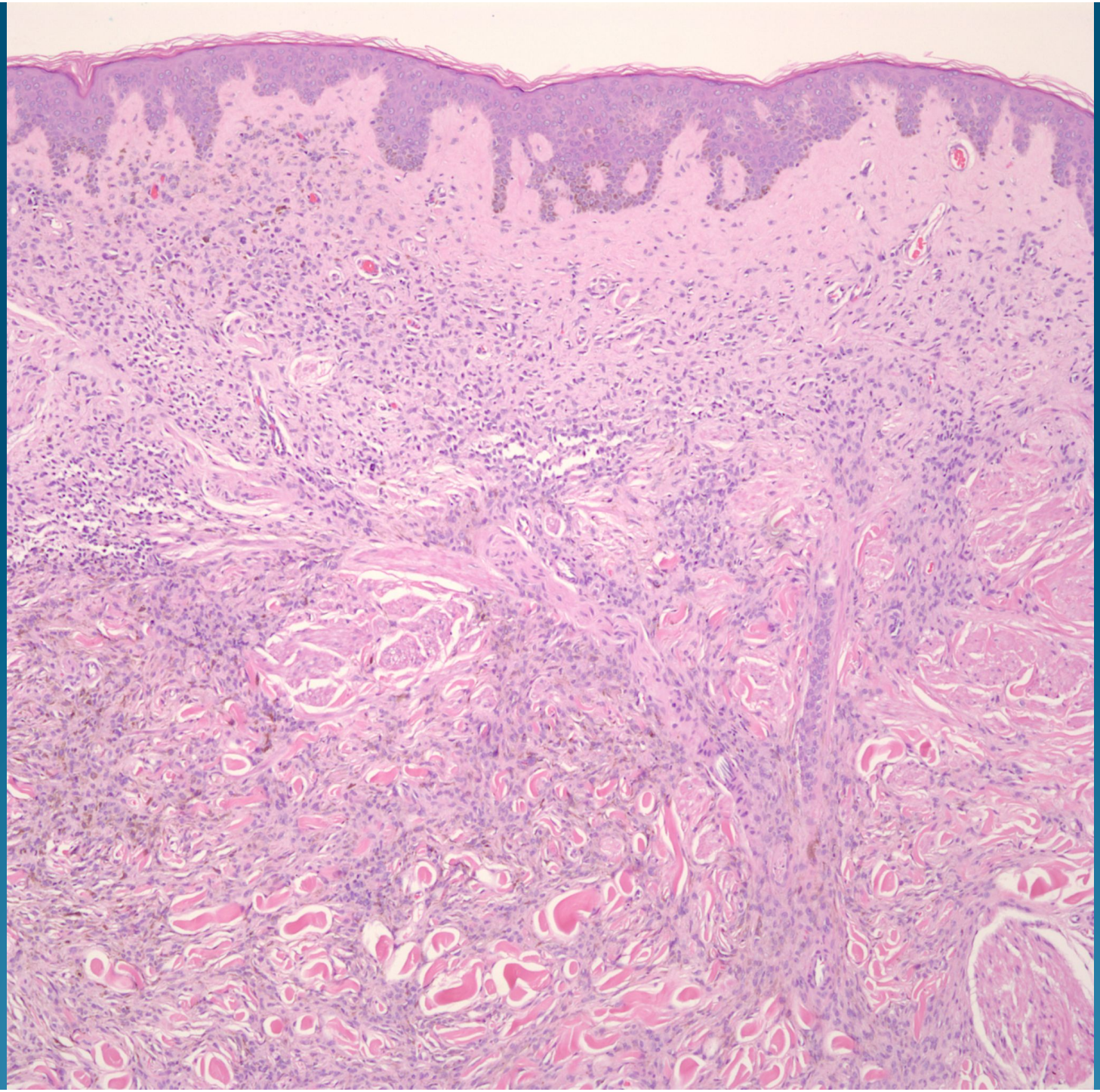

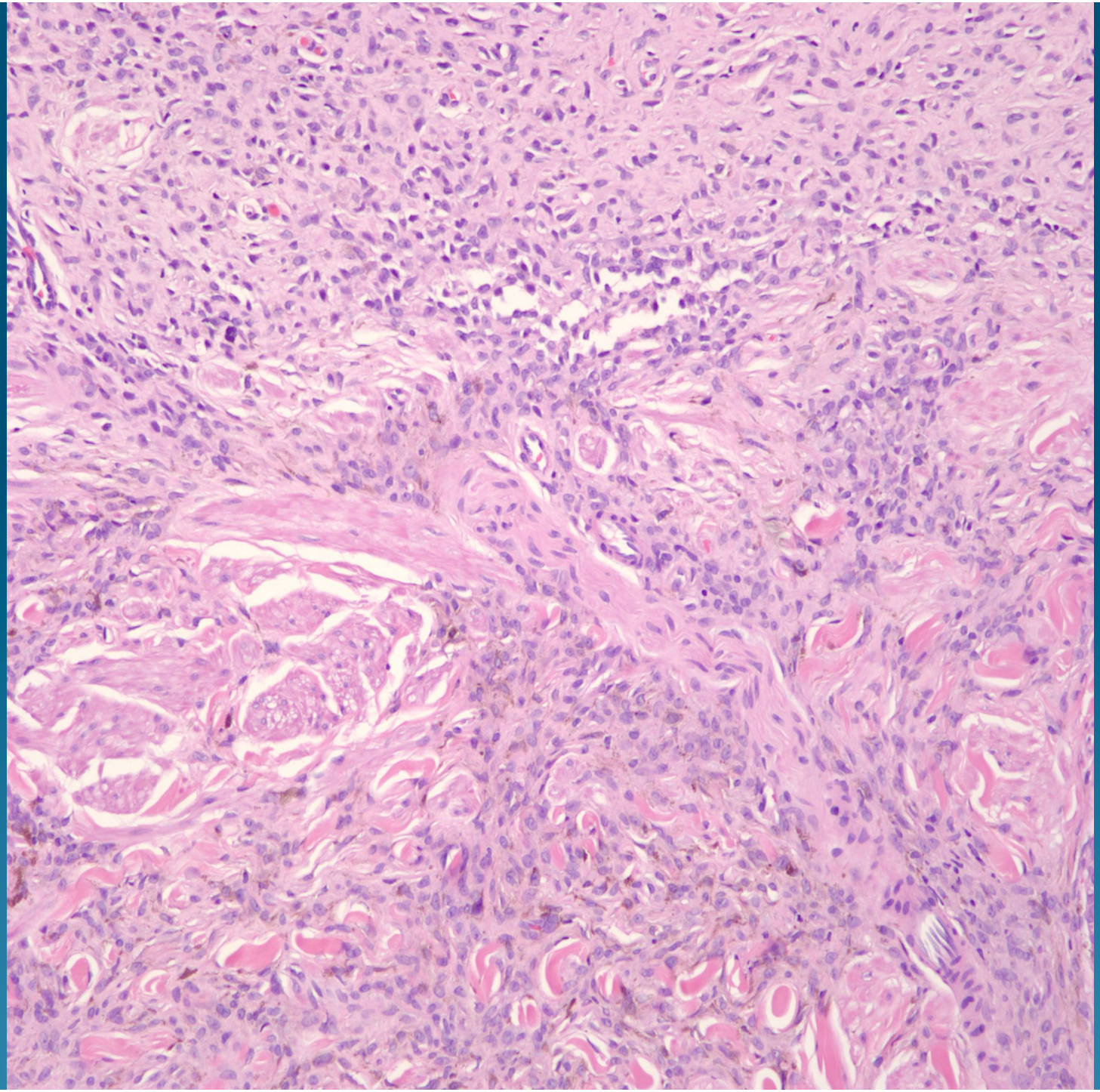

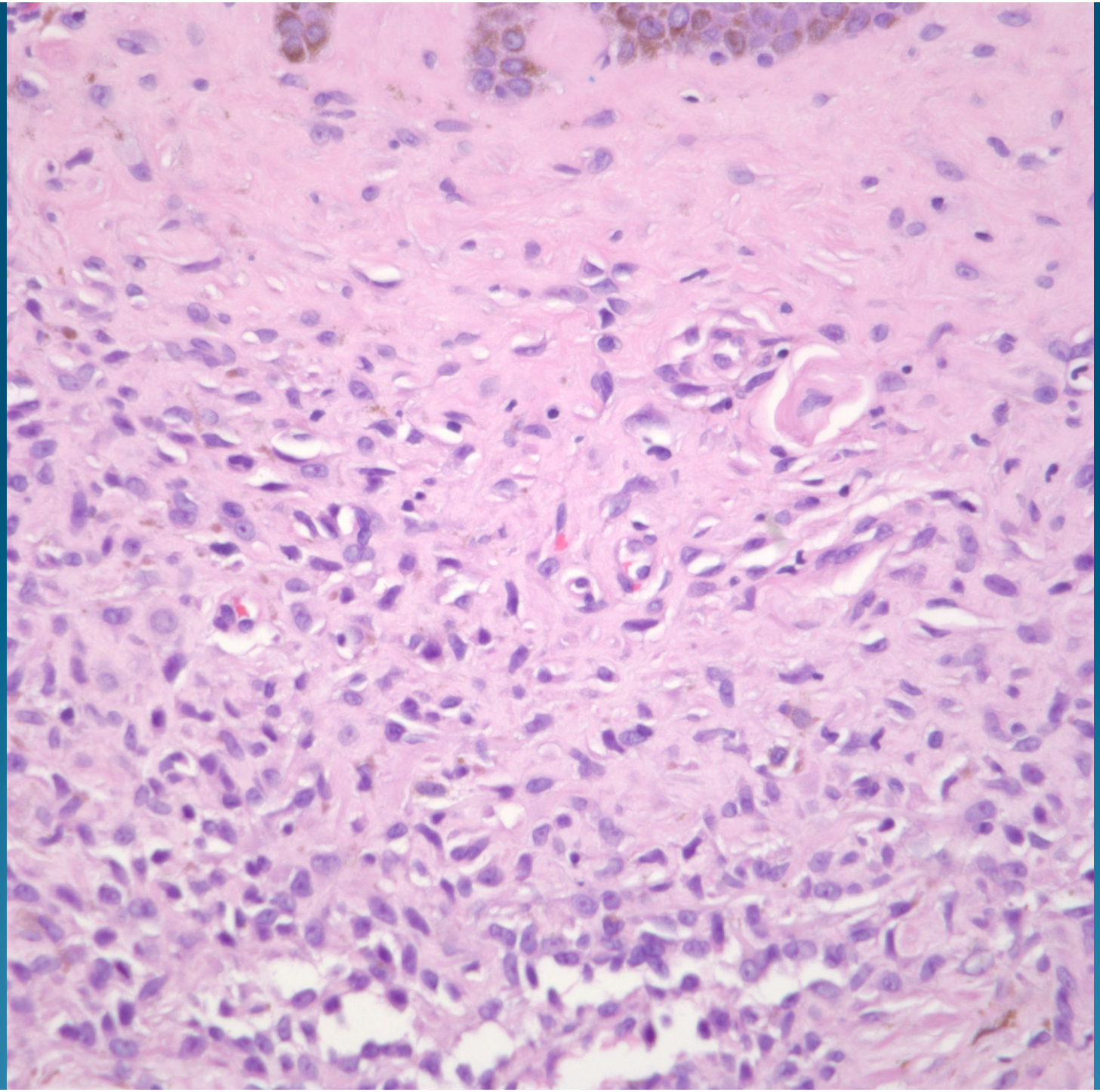

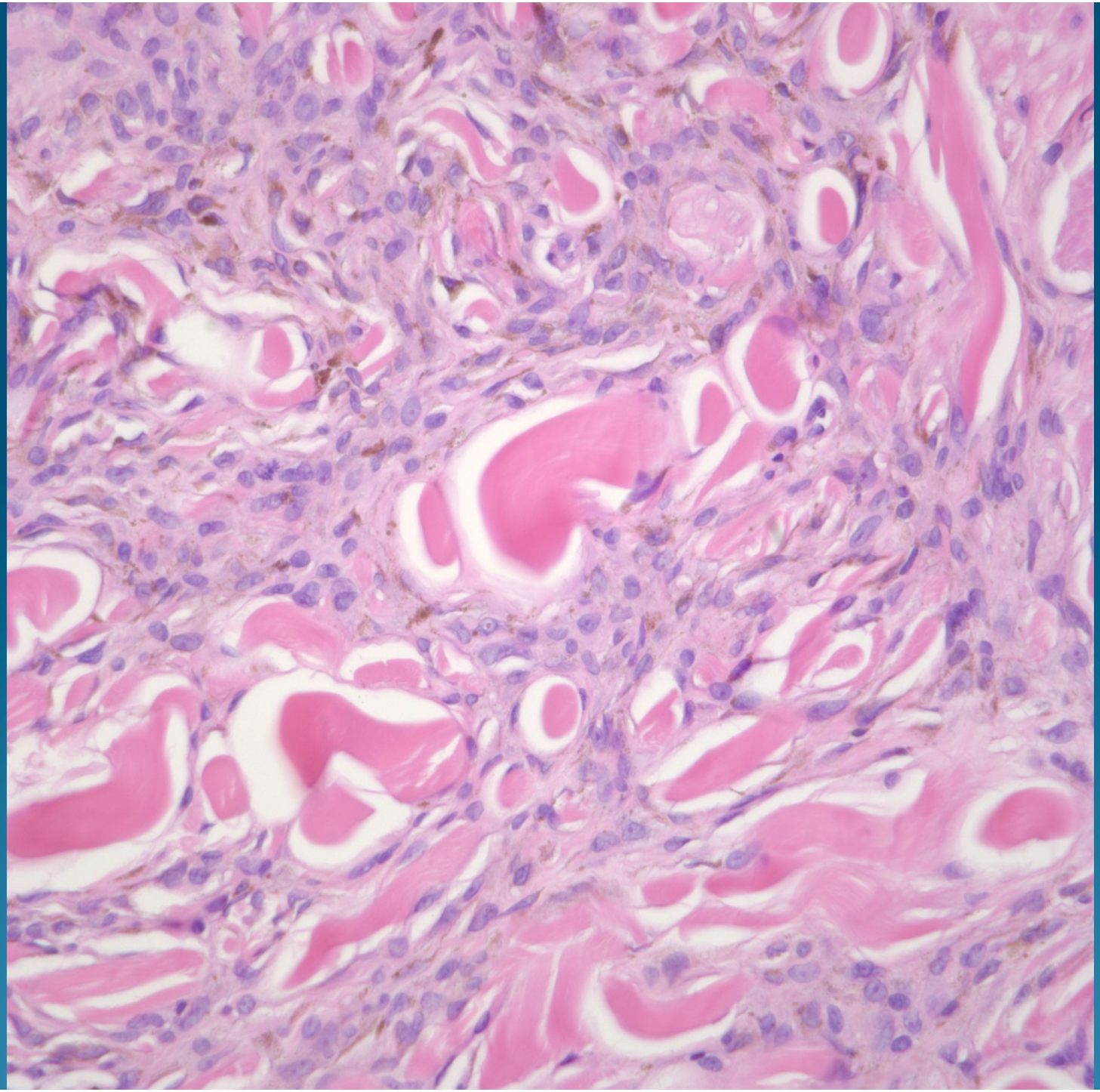

Combined Melanocytic Nevus (Intradermal nevus and blue nevus)

Pearls

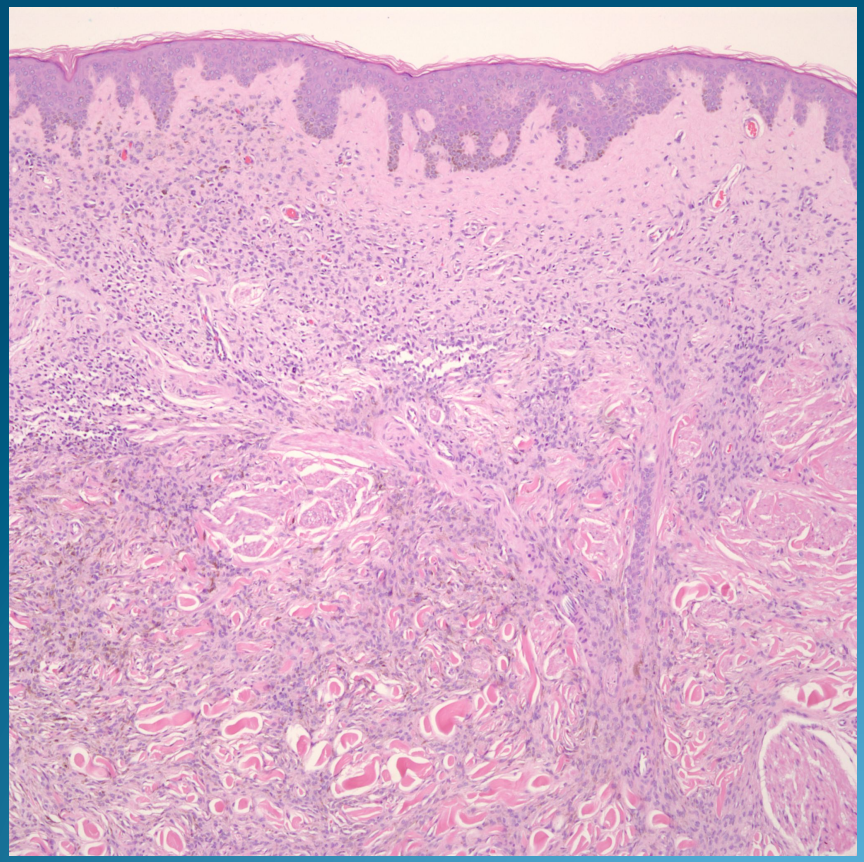

- Combined refers to conventional melanocytic nevus arising with other acquired or congenital nevus
- Melanocytes may merge
- Clinically and histologically heterogeneous

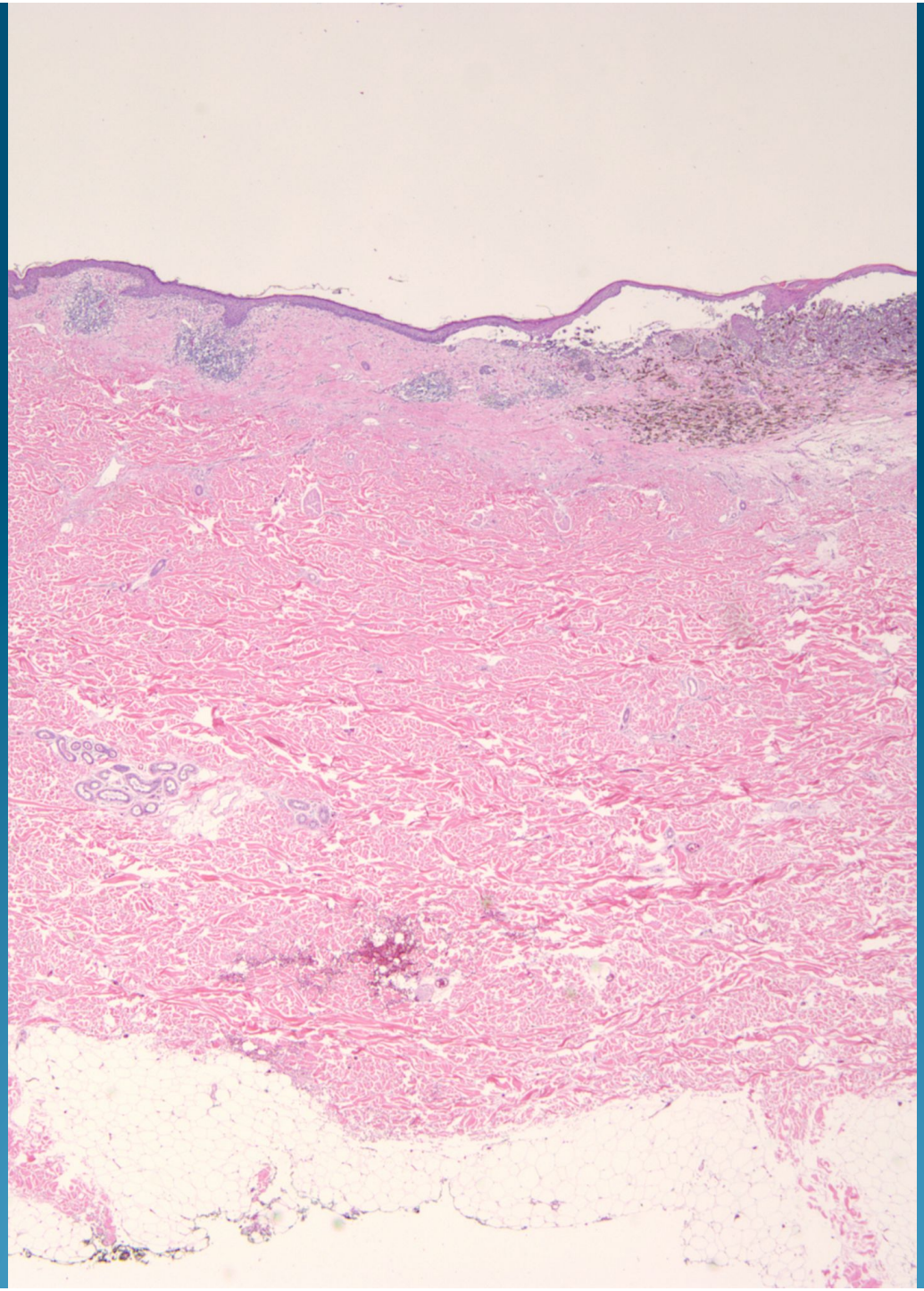

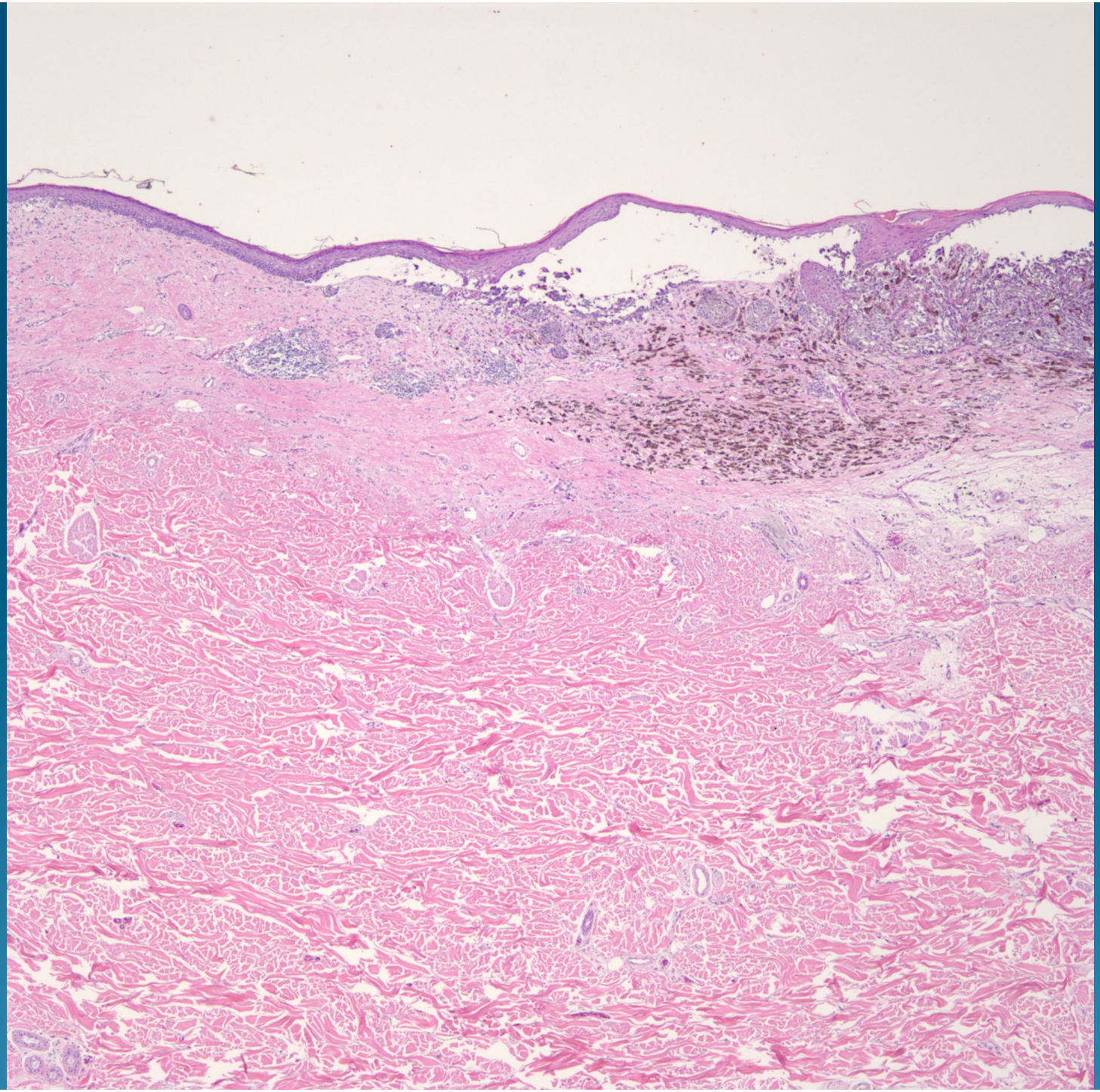

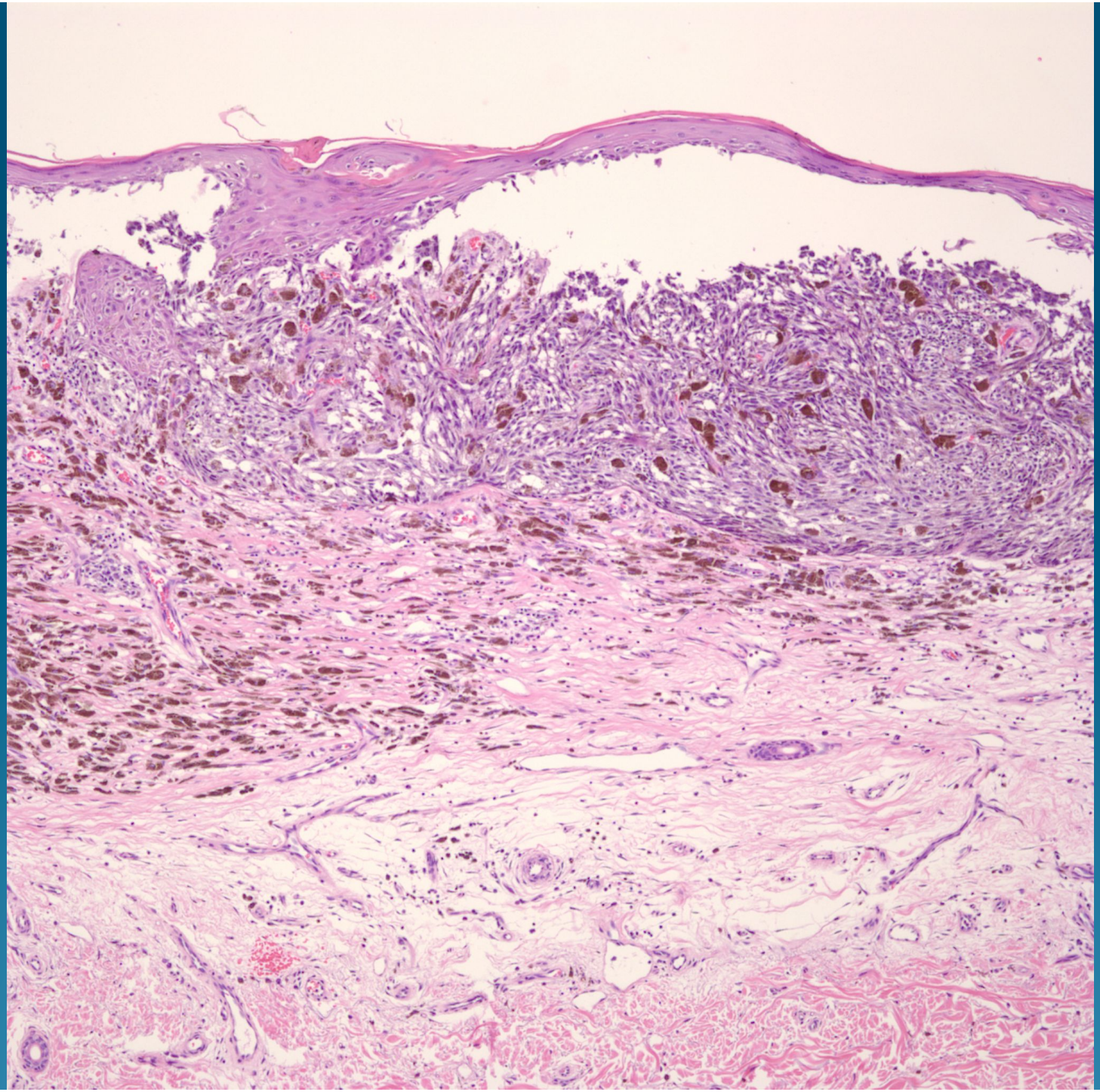

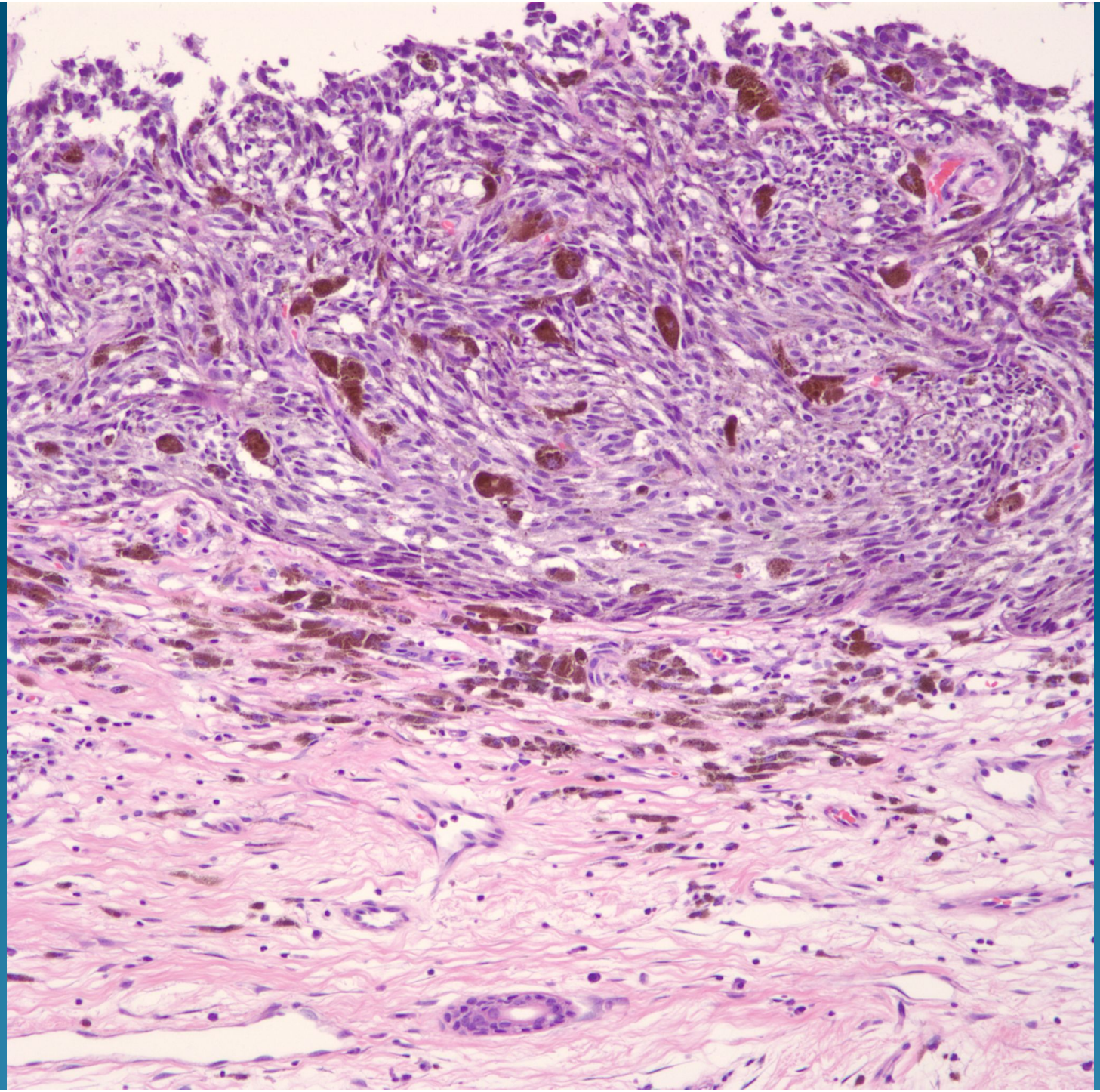

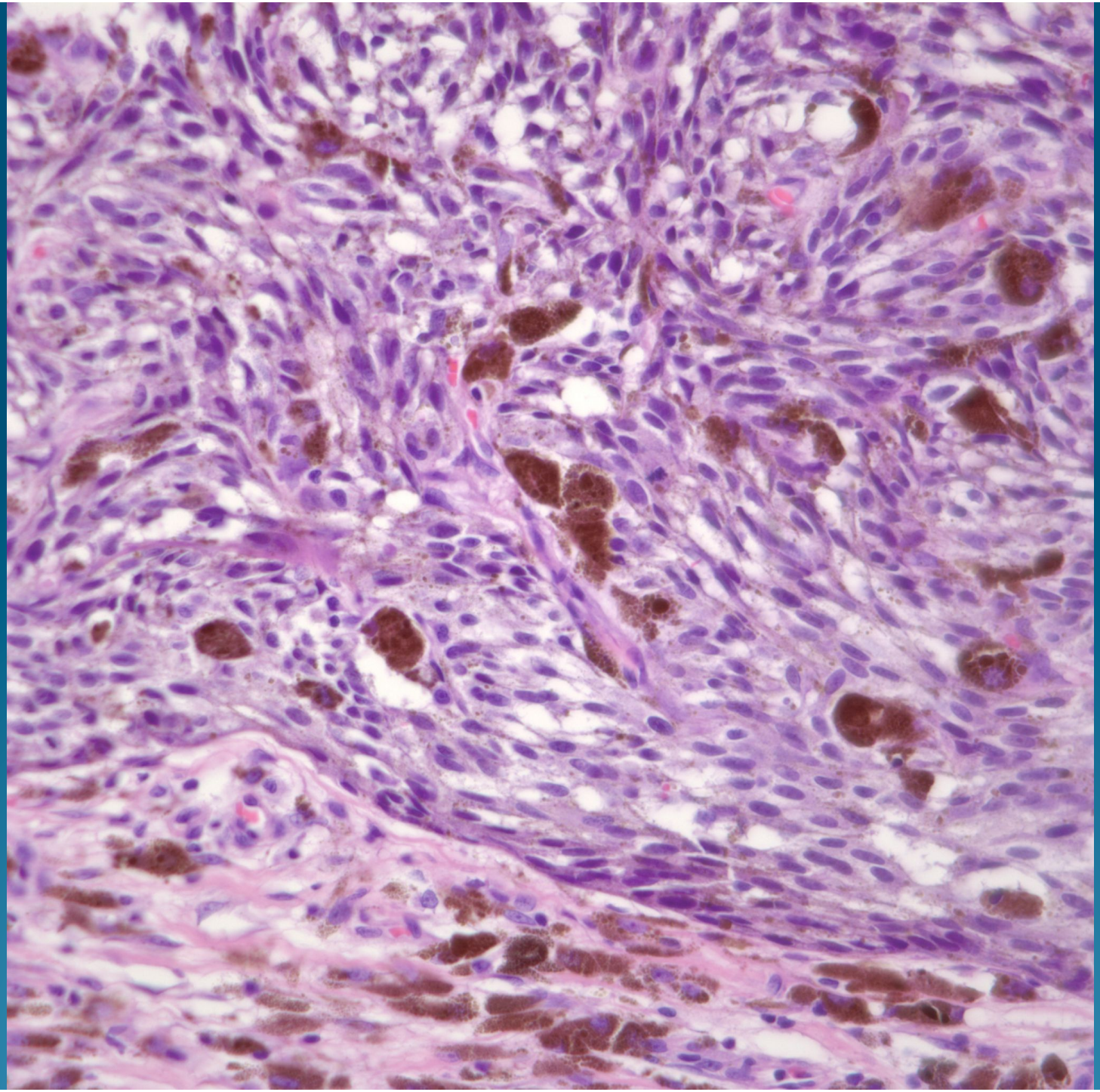

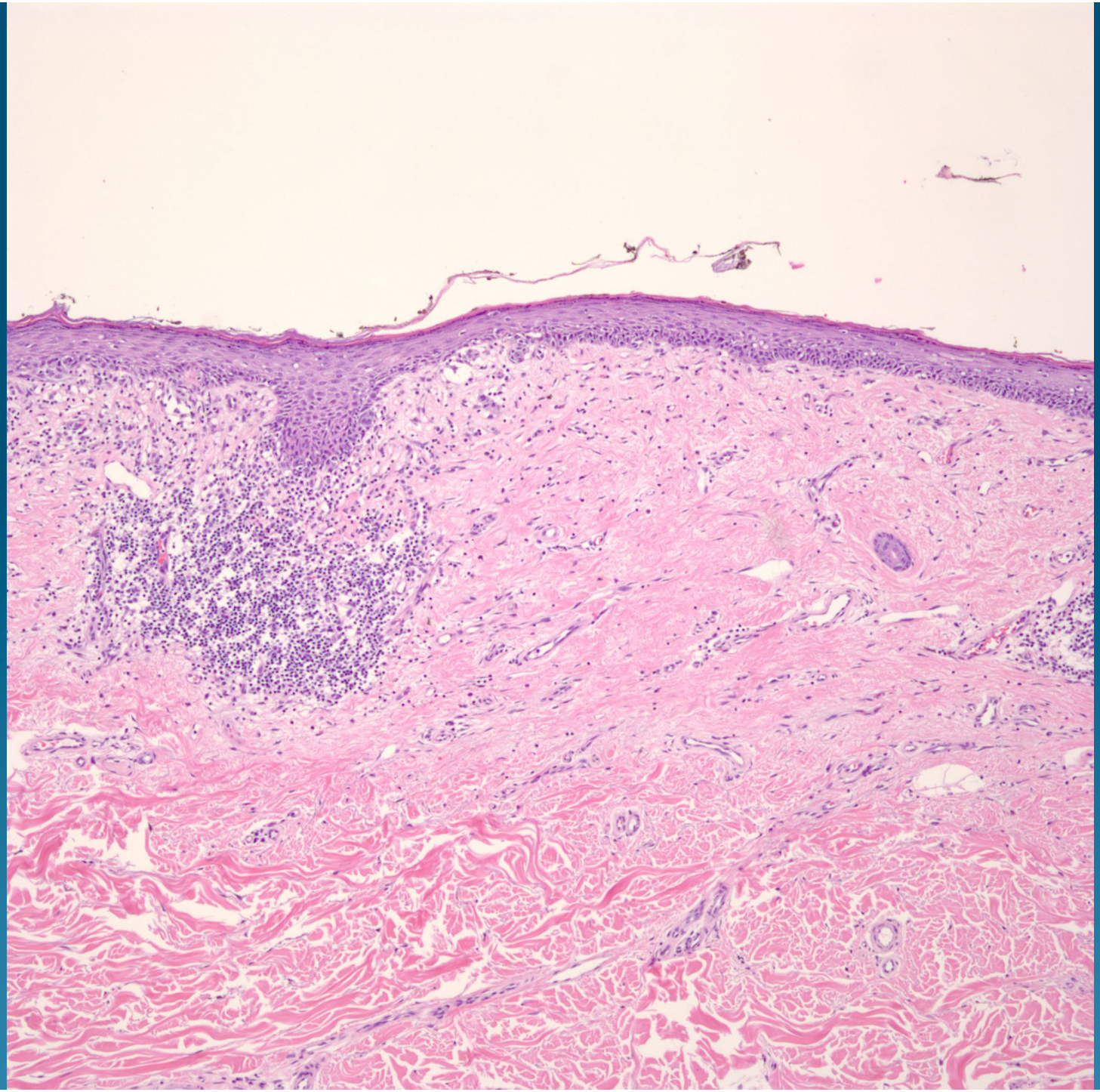

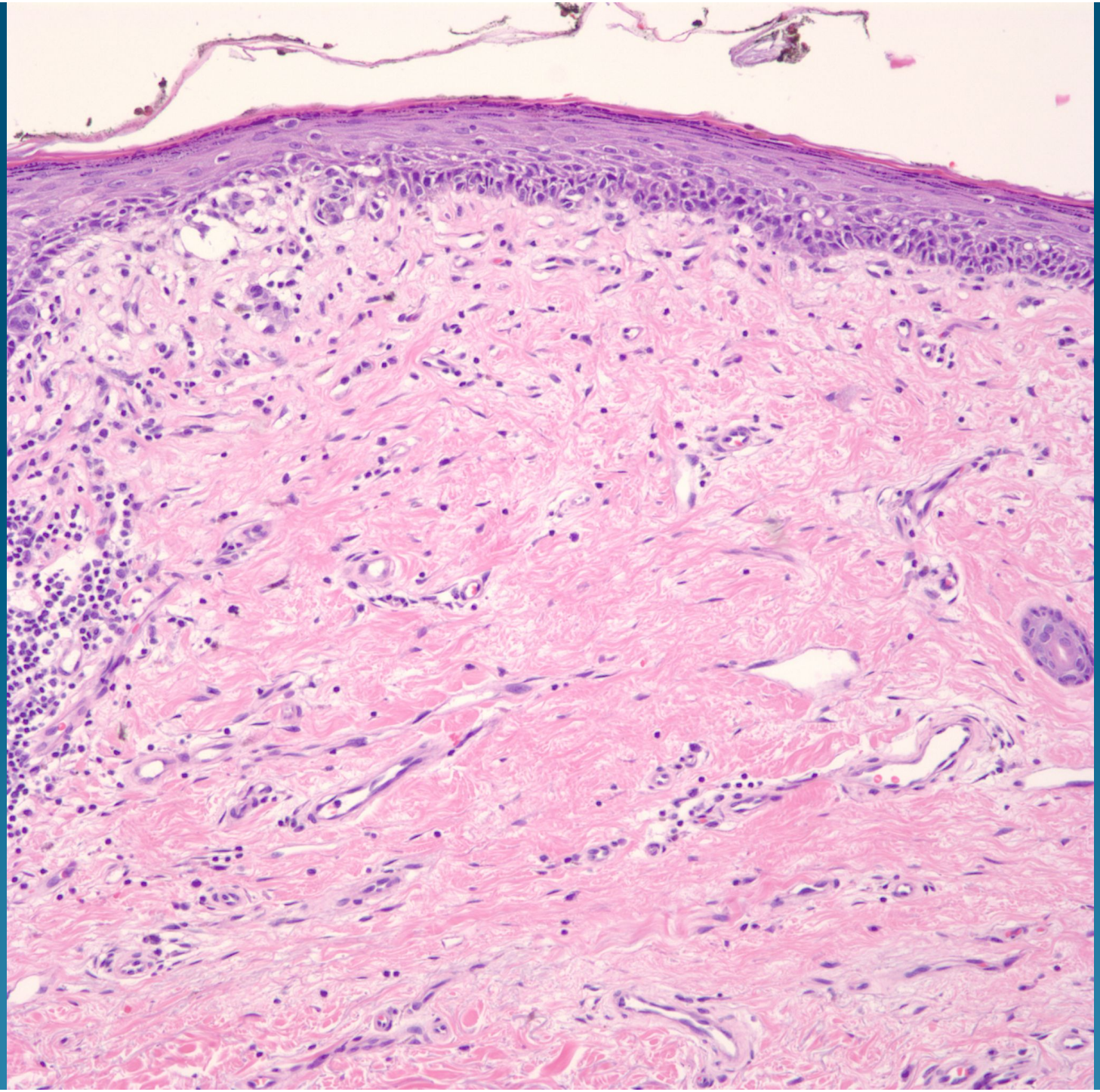

Malignant Melanoma with Regression

Pearls

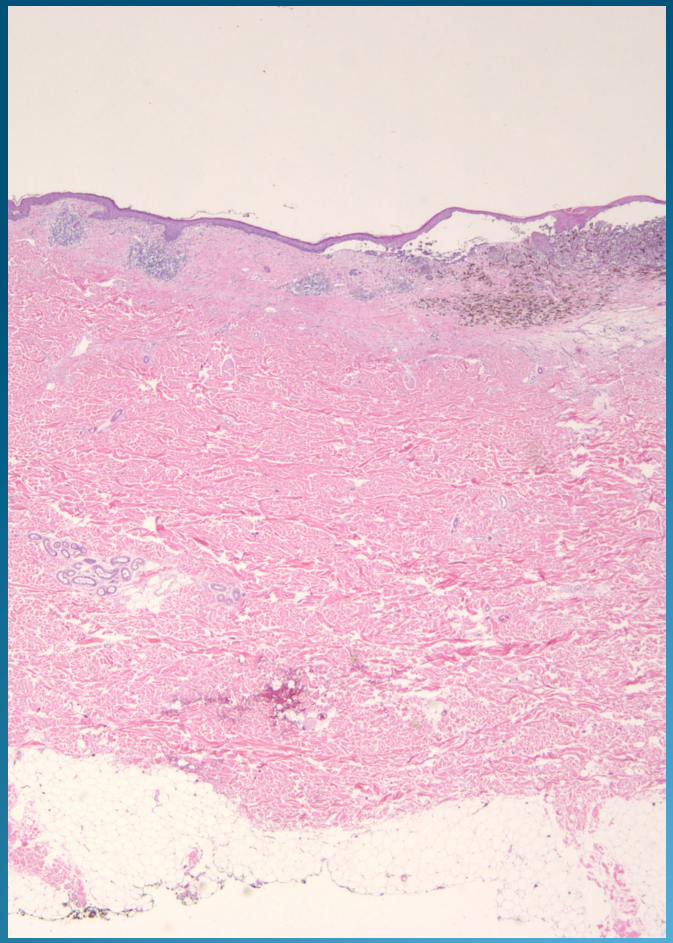

- Regression characterized by fibroplasia and scar-like changes with telangiectasia, flattening of the rete ridges and/or epidermal atrophy, melanophages, drop out of melanocytes
- Note in this case regressed areas arising adjacent to melanoma-but atypical junctional melanocytes still present (latter is inconstant finding)